

## Surgical management of cloacal malformations

Alberto Peña\*, Marc Levitt

Department of Pediatric Surgery, Schneider Children's Hospital, 269-01, 76th Avenue, New Hyde Park, NY 11040, USA

### KEYWORDS ;

Cloaca;  
Anorectal  
malformations;  
Congenital urogenital  
defects

**Summary** Cloaca is defined as a defect in which the urinary tract, the vagina and the rectum are fused, creating a single common channel, and opening into an orifice at the site of the normal urethra. Correct management includes an early diagnosis and adequate treatment from the newborn period. We believe that these patients are frequently misdiagnosed and consequently mistreated.

The analysis of our experience with the treatment of 330 cases allowed us to make specific recommendations to improve the management of these patients.

During the first 24 h of life, emphasis is placed on the recognition and treatment of potentially lethal associated defects, mainly urologic, oesophageal or cardiac. The baby should not be taken to the operating room without ruling out these associated defects.

The basic principles of the main repair are delineated. Patients suffering from cloacas with common channels shorter than 3 cm can be treated by a general paediatric surgeon, provided he or she is familiar with the procedure and observes a delicate and meticulous technique. Patients suffering from cloacas with common channels longer than 3 cm belong, by definition, to a more complex type of deformity that, in order to be repaired, requires a surgeon with more experience as well as knowledge of paediatric urology.

Sixty percent of all our patients enjoy voluntary bowel movements (VBM). Seventy percent of all patients with a common channel longer than 3 cm require intermittent catheterization to empty their bladder, whereas 20% of those born with a common channel shorter than 3 cm require such a manoeuvre. All patients must be followed on a long-term basis in order to evaluate sexual function and care for obstetric issues.

© 2003 Published by Elsevier Ltd.

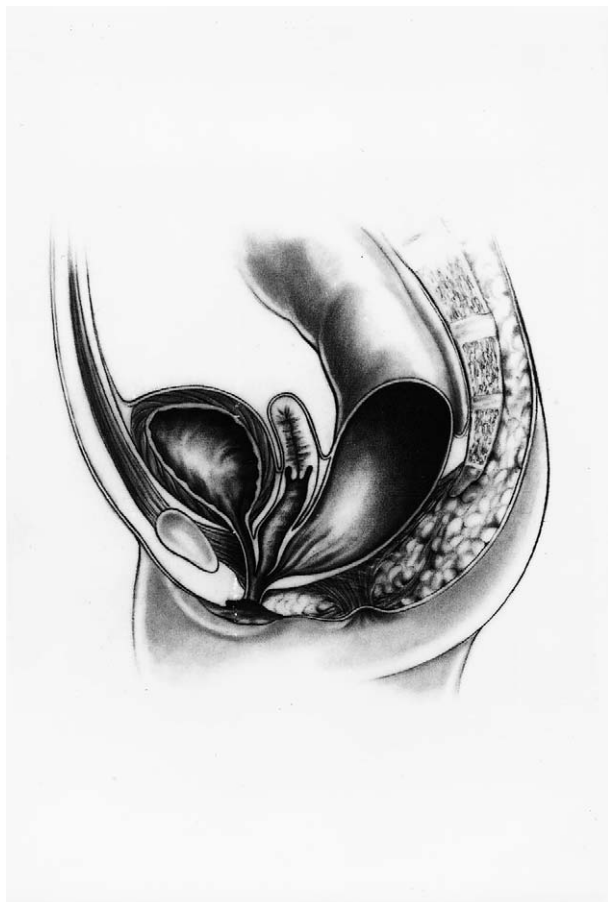### Introduction

Cloacal malformations comprise a spectrum of defects that occur in female patients. The anatomic common denominator is the junction of the urinary tract, genitalia and rectum into a single channel, opening onto the perineum in a single orifice, usually located at the site of the normal urethra (Fig. 1). All of these malformations can be corrected anatomically, but a significant number of patients never achieve normal urinary or bowel

function. The spectrum of defects includes complex malformations with serious anatomic deficiencies affecting the pelvic innervation, spine and lower extremities. At the other end of the spectrum, there are patients with defects that can be corrected anatomically, re-establishing an almost normal function for urinary and bowel control. With modern medical and surgical techniques, all patients can be maintained completely clean of stool and dry of urine, either because they achieve bowel and urinary control or because we keep them dry and clean by artificial means.

Cloacal malformations were thought to be very unusual defects. Recent evidence indicates that these defects are more common than previously thought.<sup>1</sup> Mainly in the past, but unfortunately, still

\* Corresponding author. Department of Pediatric Surgery, Schneider Children's Hospital, 269-01, Albert Einstein College of Medicine, New Hyde Park, NY 11040, USA. Tel.: +1-718-470-3636; fax: +1-718-347-1233  
E-mail address: psarp@lij.edu (A. Peña).



**Fig. 1** Diagram showing a cloaca. The rectum, vagina and urethra are fused together forming a common channel.

to some degree at present, many of these babies are misdiagnosed as having 'recto-vaginal fistulae' and consequently are managed incorrectly. The neonatal diagnosis and management of babies born with cloacas are rapidly evolving. Unfortunately, many babies are still misdiagnosed and mistreated.

Babies born with cloacas have a significant number of potential neonatal problems that must be addressed by neonatologists, paediatric surgeons and urologists.

### Materials and methods

A retrospective review of our experience was conducted. It included 330 cases of cloacas operated on by the senior author from 1982 to the present. The patients and/or parents have been contacted systematically by letter, phone or by follow-up visits once a year. One hundred and ninety-three cases were included for functional evaluation (bowel and urinary control) since 29 cases were lost to follow-up and 108 are still younger than 3 years. The clinical charts and radiology files were

**Table 1** Associated defects

Vesico-ureteral reflux	98/193	50.80%
Cardiac defect	55/149	36.90%
Tethered cord	26/77	33.80%
Hydronephrosis	90/305	29.50%
Spinal defects	49/180	27.20%
Two hemivaginas	79/305	25.90%
Hydrocolpos	77/305	25.20%
Absent kidney	44/305	14.40%
Oesophageal atresia	31/305	10.20%

**Table 2** Functional results

Urinary continent	104/193	54%
Dry with intermittent catheterization	47/193	24%
Dry with diversion	42/193	22%
VBM	94/156	60.30%
Soiling	115/163	70.60%
VBM and no soiling	44/156	28.20%

reviewed with special emphasis on associated defects, management problems and complications.

### Results

Associated defects are presented in Table 1 and functional results can be seen in Table 2. Recommendations on the management were formulated based on these observations.

### Prenatal diagnosis

Cloacal malformations cannot be diagnosed reliably in the prenatal period. There are a number of anatomic in utero findings that are highly suggestive of the presence of a cloaca. These include:

- hydronephrosis,
- an intrapelvic collection of fluid (hydrocolpos),
- dilated distal bowel,
- spinal and/or sacral malformations,
- absent kidney.

When present in a female foetus, these findings are highly suggestive of a cloacal malformation. Technical advances related to the in utero diagnosis are expected to improve the accuracy of the prenatal diagnosis.

### Neonatal diagnosis

The diagnosis of a cloaca is a clinical one. We have been impressed by the number of patients, born at other institutions, with a cloacal malformation and

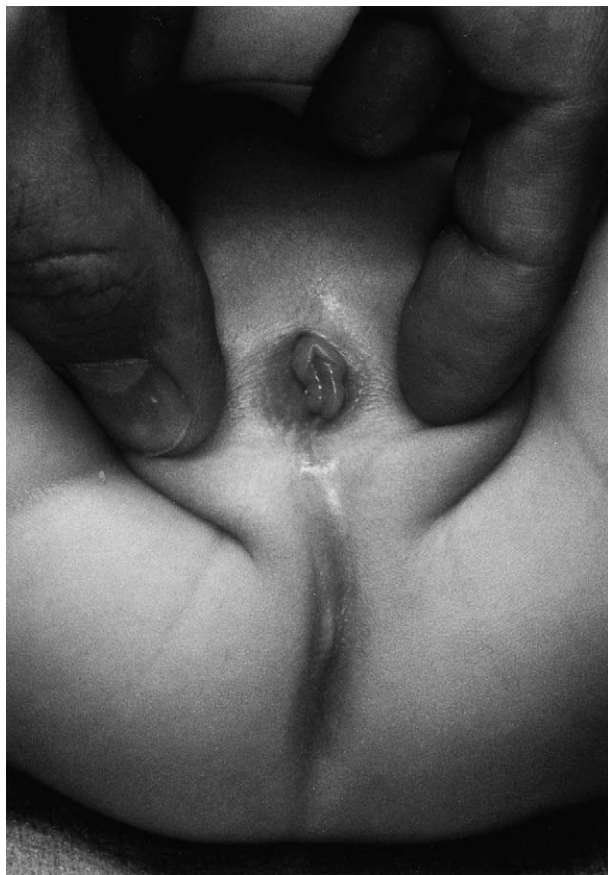

Fig. 2 Perineum of a patient with a cloaca. There is only one orifice.

misdiagnosed as having 'recto-vaginal fistulas'. Thirty patients in our series belong to this category. With this misdiagnosis, the surgeon often repaired the rectal component of the malformation, and left the urogenital sinus untouched.<sup>1</sup> The patient missed the opportunity to have the malformation repaired in a single procedure. Pure recto-vaginal fistulas are, in fact, extremely unusual defects. We have also been impressed by the high proportion of patients, born at other institutions, diagnosed incorrectly to suffer from intersex anomalies when in fact they had persistent cloacas.

A female baby born with no anal orifice and with a single perineal orifice has, by definition, a persistent cloaca (Fig. 2) A simple inspection of the perineum will allow the clinician to establish this diagnosis. The diagnosis of a cloaca must elicit a series of concerns and decisions related to the potential problems that the neonate may have.

### Potential neonatal problems

Thirty percent of our cloaca patients suffer from hydronephrosis, 25% from hydrocolpos (distended

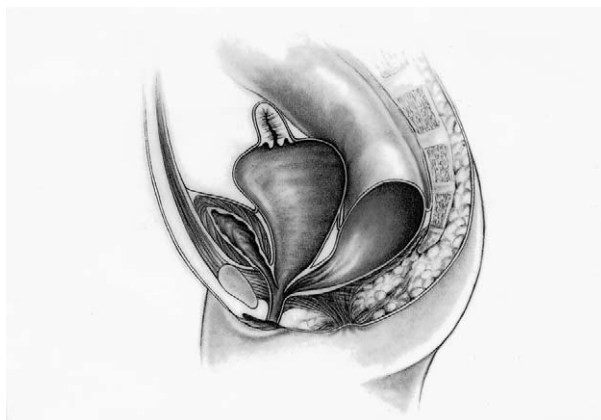

Fig. 3 Diagram showing the anatomy of a patient with a cloacal anomaly and hydrocolpos.

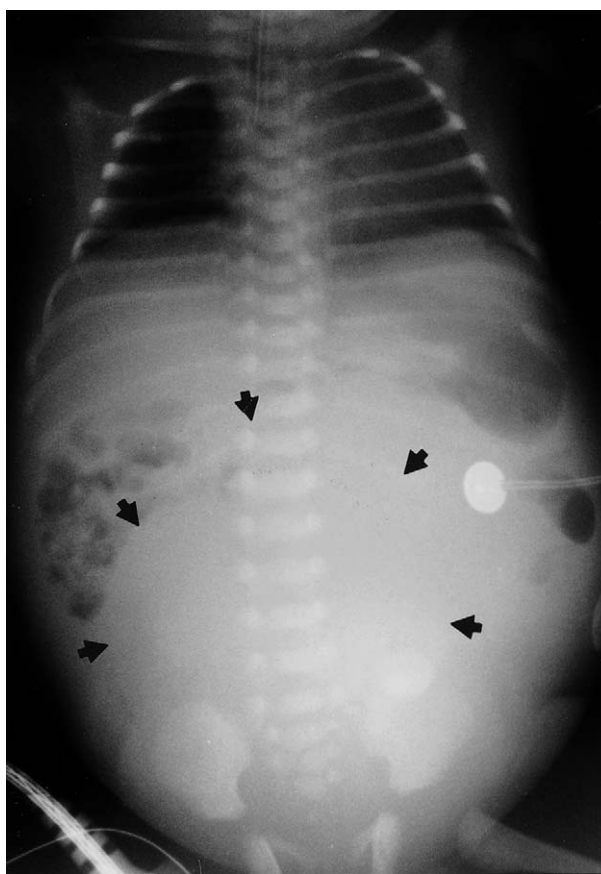


Fig. 4 Abdominal radiograph of a newborn baby with a cloaca and a very large hydrocolpos.

vagina filled with fluid) (Figs. 3 and 4) and 50% from vesico-ureteral reflux. The degrees of hydronephrosis and hydrocolpos vary significantly from one patient to the other. In severe cases, the babies may even suffer from respiratory distress because of the magnitude of the abdominal distension from

the dilated vagina. Most frequently, the hydronephrosis is secondary to the extrinsic mechanical obstruction of the lower ureters produced by the hydrocolpos.

Thirty-seven percent of our patients suffered from some cardiac defect, including patent ductus arteriosus, atrial septum defects, ventricular septum defects, tetralogy of Fallot and more complex malformations. Six percent required a surgical intervention; the rest had no haemodynamic implications. Ten percent of patients had oesophageal atresia, 27% suffer from spinal malformations and 34% from tethered cord.

The decision-making process during the first 24 h of life is extremely important and must be based on these statistics. During this time, the most important pressing question—'Does the patient have an associated defect that threatens her life?'—must be answered. To answer this question, the baby must undergo an abdominal ultrasound with the specific goal of making the diagnosis of hydronephrosis and/or hydrocolpos. If the kidneys are normal and there is no hydrocolpos, no further urologic studies are necessary.

The baby must be observed for the presence of symptoms and signs of oesophageal atresia (respiratory distress, saliva in the mouth, episodes of cyanosis and inability to swallow). An echocardiogram will rule out the presence of a cardiac malformation. A plain radiograph of the sacrum and lumbar spine will rule out the presence of spinal malformations, and an ultrasound of the spine will diagnose a tethered cord when present.

In the presence of hydronephrosis, further urologic evaluation is warranted. A catheter should be passed through the single perineal orifice and water-soluble contrast material is injected, hopefully into the bladder, to rule out the possibility of vesico-ureteral reflux. Occasionally, these patients are incapable of emptying the bladder. This is important information that the paediatric surgeon or paediatric urologist needs, prior to taking the baby to the operating room for the colostomy. Some of these patients have a very narrow urethra and they benefit from a suprapubic cystostomy or a vesicostomy. If the patient has bilateral hydronephrosis and hydrocolpos, she will benefit from drainage of the vagina or vaginas with a tube (tube vaginostomy), to be performed at the same time as the colostomy opening. The baby should never be taken to the operating room without this evaluation. All the distended genitourinary structures may require decompression. It is not uncommon for these babies to be subjected to a colostomy, only to develop urosepsis

1 or 2 days later, because they suffer from an untreated urologic problem.

In the presence of hydronephrosis and hydrocolpos, some babies are subjected to unnecessary ureterostomies because the surgeon did not know that drainage of the vagina is usually adequate to take care of the problem of hydronephrosis. All these patients benefit from the opening of a decompressive colostomy, but the colostomy does not have to be performed during the first 24 h of life as these patients are not born with a distended bowel. However, the opening of a colostomy should not be postponed much more than 24 h because, after that, babies run into the risk of colonic perforation.

### Colostomy

When the baby is taken to the operating room, endoscopy will help delineate the anatomic characteristics of the malformation, but will not contribute much to the decision-making process in the newborn period. The endoscopic study will allow the surgeon to learn about the length of the common channel, which has important functional prognostic implications and helps plan the definitive operation. These issues will be discussed later.

The colostomy should be opened in the descending colon, ensuring that enough length of sigmoid is left distal to the colostomy to guarantee that the pull-through of the rectum will be possible. The stomas must be separated to ensure that the proximal, functional stoma can be covered with a stoma bag, avoiding contamination of the mucous fistula (distal stoma). Loop colostomies are contraindicated because they may allow the passage of stool into the genito-urinary tract.

The most common causes of sepsis in the first days or weeks of life are untreated hydronephrosis, faecal contamination of the urinary tract from a loop colostomy, incapacity to empty the bladder in the presence of vesico-ureteral reflux, or a combination of these.

### Vaginostomy

All hydrocolpos must be drained, usually by placing a suprapubic tube. Sometimes, the hydrocolpos is so big that it is possible for the surgeon to open a vaginostomy connecting the vagina directly to the skin. Twenty-six percent of our series of 330 patients with cloaca have two hemivaginas divided by a septum. The surgeon must ensure that both hemivaginas are drained at the time of the

operation. In order to do that, it is sometimes necessary to open a window in the vaginal septum to ensure that both vaginas are drained. Not draining a hydrocolpos exposes the patient to persistent hydronephrosis and/or infection of the hydrocolpos (pyocolpos). The infection and possible subsequent perforation of a hydrocolpos is a catastrophic event that requires an emergency laparotomy and usually damages the vagina permanently, making it unusable for a repair. We have seen this happening to two patients. Some surgeons try to drain the hydrocolpos by the use of catheters passed through the single perineal orifice. The problem with this manoeuvre is the inability to control as to where the tip of the catheter goes, because it is essentially a blind manoeuvre. They try to train the care-givers to drain and irrigate the hydrocolpos by passage of the catheter, which is frequently unsuccessful.

Occasionally, a patient may also need a vesicostomy or a suprapubic cystostomy when the surgeon has evidence that the urethra is so narrow that it is incapable of draining the bladder. In the presence of massive vesico-ureteral reflux and incapacity to empty the bladder, a vesicostomy is indicated.

When the distended colon has been diverted, and the hydrocolpos and the urinary tract have been drained, the patient will recover uneventfully, and can be rapidly discharged from the hospital.

Two to four weeks after discharge, the patient is brought to the radiology department to perform a very important imaging procedure called a 'high-pressure distal colostogram'.<sup>2</sup> A Foley catheter is passed through the mucous fistula (distal stoma), the balloon is inflated with 1 or 2 cm<sup>3</sup> of water, and hydrosoluble contrast material is injected under fluoroscopy while applying traction to the balloon to avoid leakage of the contrast material. By doing this, the anatomy of the malformation can be delineated. The rectum, as well as the connection between the rectum and the genito-urinary tract, is visualized. The contrast material usually goes into the vagina or hemivaginas, and in some cases, it even goes into the bladder. If the bladder or vaginas were not filled with this injection, a catheter is passed through the single perineal orifice and the study is completed, injecting contrast material from below. Figs. 5–7 illustrate some of the most common images obtained with these studies.

This radiologic evaluation will help the surgeon to plan the main repair. He or she will be able to determine whether the entire defect can be

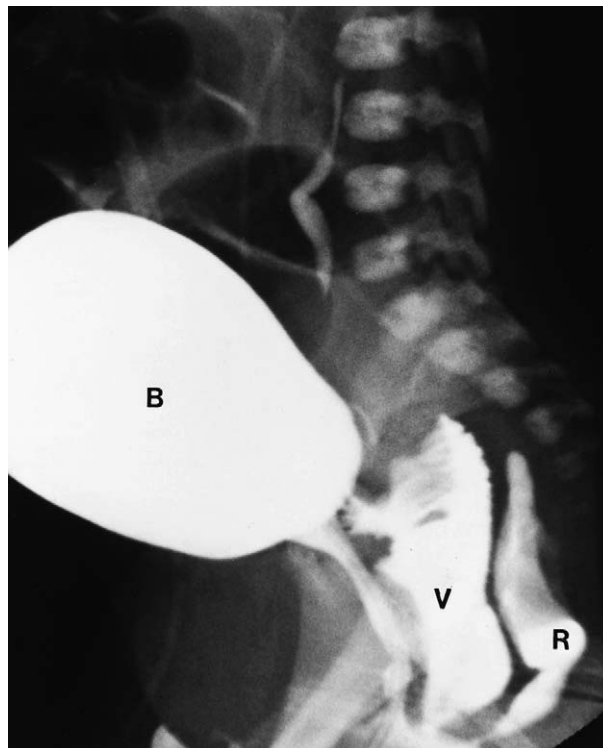


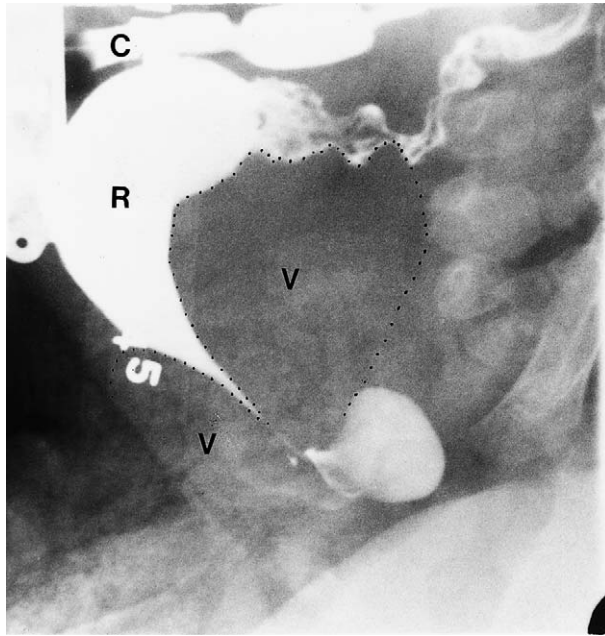
Fig. 5 Radiologic study done with hydrosoluble contrast material showing the rectum (R), the vagina (V) and the bladder (B).

repaired posterior sagittally, or if a laparotomy will be necessary.

The main repair of the malformation is performed when the surgeon has evidence that the baby is growing and developing normally. The age of operation depends on the experience of the surgeon with the procedure.

### Main Repair

This is a sophisticated operation that requires a great deal of experience, and a meticulous and delicate technique.<sup>3</sup> The operation consists of separating the rectum from the genito-urinary tract and pulling it down to be placed within the limits of the sphincter. The urogenital sinus is mobilized as a unit, enough to achieve a successful repair and having at the end, visible and separate urethral, vaginal and rectal orifices.<sup>4</sup> This manoeuvre is called 'total urogenital mobilization'. It was introduced in 1997 and significantly facilitated the repair of these defects.<sup>4</sup> When the patients have a common channel shorter than 3 cm, the malformation can usually be repaired by approaching the patient posterior sagittally without opening the abdomen. When patients have a common channel longer than 3 cm, it is usually necessary not only to

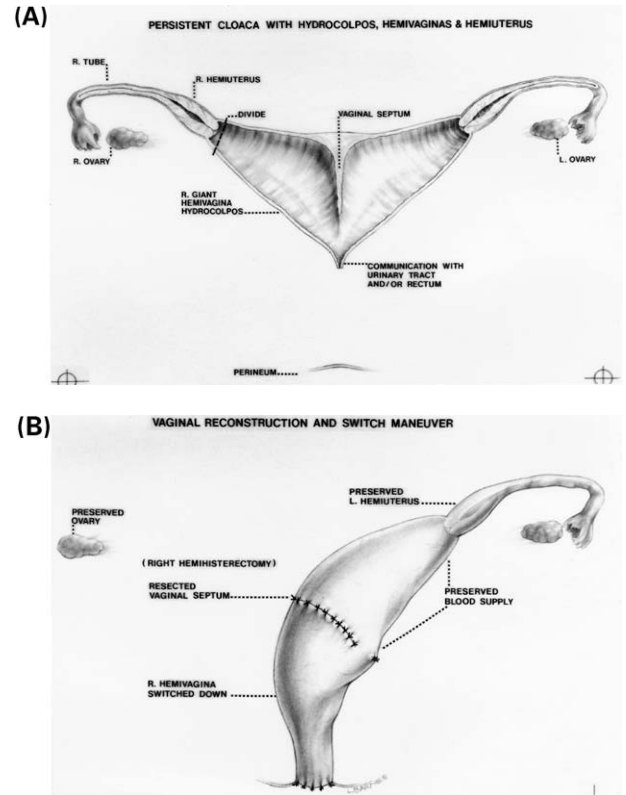


**Fig. 6** Distal colostogram of a cloaca. Injection of contrast was done through a transverse colostomy (C). A very dilated rectum (R) opens in the vaginal septum that separates two very dilated vaginas (V).

approach the patient posterior sagittally, but also to open the abdomen to complete the repair and to reach a very high rectum, a very high vagina or both.

We believe that the operation designed for cloacas with common channels shorter than 3 cm is fairly reproducible and can be performed by most paediatric surgeons, provided they have adequate training and familiarity with the operation. When dealing with cloacas with a common channel longer than 3 cm, we believe that patients should be operated on in special referral centres where surgeons have more experience with these types of defects. The procedure must be done by a paediatric surgeon who also has special training in urology, or in collaboration with a paediatric urologist with experience in this particular subject.

In this particular group of patients, the patient is approached both posterior sagittally and abdominally. The vagina must be separated entirely from the urinary tract; this is the most delicate and technically demanding part of the procedure. The separation of the large vagina from the urinary tract requires opening of the bladder in order to introduce ureteral catheters. This manoeuvre protects the ureters, which run right through the common wall that separates the vagina from the bladder. Once the vagina has been separated completely, a series of decisions must be taken that



**Fig. 7** Vaginal switch. (a) Two hemivaginas, bilateral hydrocolpos and a long common channel are the anatomic set-up that represents an indication for the vaginal switch. (b) The vaginal septum was resected, both hemivaginas were tabularized, the right hemiuterus and tube were resected and the dome of the right vagina was switched down.

require experience and knowledge. The decisions vary depending very much on the anatomic characteristics of the cloaca. The worst anatomic combination is one of a very highly located and small vagina, or vaginas. These vaginas cannot be mobilized and pulled down to the perineum. Under these circumstances, the patient will require a vaginal-replacement procedure. Ideally, we use a piece of colon to replace the vagina, but if the colon cannot be used for whatever anatomic reason, we use small bowel. Other patients require a vaginal-replacement manoeuvre using part of a very dilated rectum with its own mesentery. Seventy-five of our patients (22%) required any one form of vaginal-replacement (Table 3).

In other cases, the two hemivaginas are very large because the patient suffers from bilateral hydrocolpos. One would expect that it would be feasible to bring these vaginas down, and yet it is not possible to do that without provoking vaginal devascularization. Interestingly, in some of these cases, the distance between both cervixes is longer

**Table 3** Vaginal replacements

Rectum	36
Small bowel	31
Colon	8

than the vertical length. When the patient has that specific type of anatomy, she will benefit from a manoeuvre called 'vaginal switch' (Fig. 7).<sup>5</sup> One of the hemiuteri is sacrificed, the vaginal septum is resected, and both hemivaginas are tubularized into a single vagina. What used to be the dome of one of the hemivaginas is switched down to the perineum. This manoeuvre allows the repair of this type of complex malformation. The blood supply of the hemivagina that is switched down is sacrificed, but the blood supply of the preserved hemiuterus and hemivagina provides enough flow to keep the pulled hemivagina alive. Twenty-nine (9%) of our patients benefitted from this manoeuvre.

In our experience, 220 patients (67%) with cloaca had a common channel shorter than 3 cm, and, therefore, were repaired without opening the abdomen. One hundred and ten patients (33%) had a longer common channel, and, therefore, required a laparotomy.

At the most complex extreme of the spectrum of cloacal malformations, we find patients that have two tiny hemivaginas attached to the bladder neck with a rectum also opening in the bladder neck. When we separate these structures, we are left with no bladder neck. In our experience, these patients benefit from closing the bladder neck and opening a temporary vesicostomy. A vaginal-replacement procedure is performed and the rectum is pulled down. When the patient reaches the age of urinary control, she will require a complex urinary reconstruction called a continent diversion.<sup>6,7</sup> It consists, most of the time, in augmenting the size of the bladder with a piece of bowel, and using the appendix or a similar structure made out of bowel as a conduit, with a one-way valve mechanism for the patient to perform intermittent catheterization to empty her bladder. Sixty patients (18%) required a continent diversion.

### Colostomy closure

The colostomy is usually closed at least 2–3 months after the main repair. If the patient was not subjected to a laparotomy during the main repair, it is during the colostomy closure that we recommend studying the patency of the Müllerian structures. The inspection is performed by passing a number

3 F feeding tube through the fimbria of the fallopian tube and injecting saline solution to confirm that the solution runs through the Müllerian structure (hemiuterus and hemivagina). We found that a significant number of patients with cloacas suffer from different degrees and types of atresias of the Müllerian structures.<sup>8</sup> When these defects are not diagnosed early in life, the patient may suffer from a characteristic series of symptoms when they reach puberty, due to having menstrual blood trapped in the abdomen. This provokes dramatic symptoms that require a laparotomy and excision of the Müllerian remnants filled with a large amount of undrained menstrual blood. We believe that if both Müllerian structures are obstructed, perhaps it is desirable not to touch them, but to make a note in the chart of the patient, and be aware of the problem to make an early diagnosis when she reaches puberty. At puberty, these patients can suffer from abdominal pain with monthly exacerbations at the time when menstruation is expected. The patient needs an evaluation to rule out the presence of trapped menstrual blood. On the other hand, we believe that if the patient suffers from unilateral obstruction of the Müllerian structures, it is better to resect those atretic hemiuteri. If the patient had a laparotomy at the time of the main repair, then that is the ideal time to check the patency of these Müllerian structures.

### Functional prognosis

When a baby is born with a cloaca, parents and doctors should have three concerns:

- bowel control,
- urinary control,
- sexual function.

The most important prognostic factors in cloacas are:

- characteristics of the sacrum,
- length of the common channel,
- associated spinal cord anomalies,
- characteristics of the sphincter.

The characteristics of the sacrum has a definite influence on faecal continence. The amount of sacral hypodevelopment can be assessed objectively by calculating a sacral ratio (Fig. 8). The length of the common channel seems to have a primary influence on urinary control. We do not yet have enough experience to discuss sexual function since the great majority of our patients are still not sexually active. A few of our patients, however, are

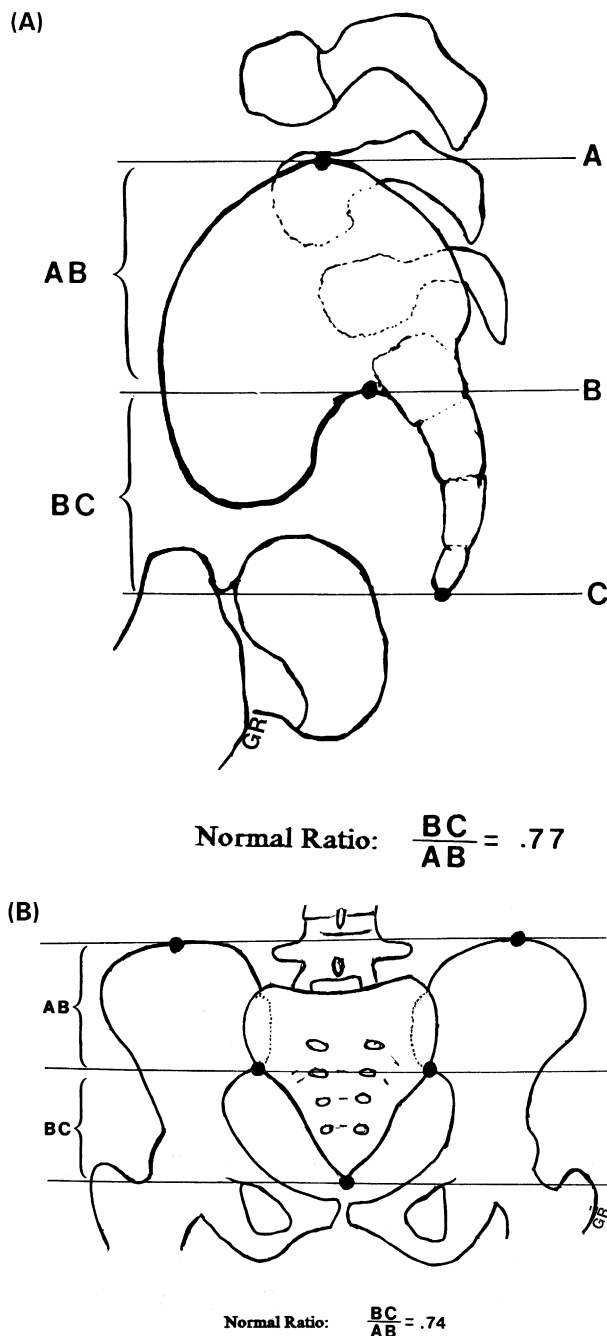


Fig. 8 Sacral ratio. (a) Antero-posterior view. (b) Lateral view.

sexually active and from them we have learned important lessons. Basically, we can say that the patients, who had a successful mobilization of their own vagina, seem to have a satisfactory sexual life. We do not have sexually active patients, who have a vagina replaced with bowel. We do not yet have patients, on whom we have operated, who have become pregnant.

Seventy percent of the patients who had a common channel longer than 3 cm require intermittent

catheterization to empty their bladders. Patients with a common channel shorter than 3 cm require intermittent catheterization 20% of the time.

Interestingly, most patients with cloacas are born with a good bladder neck. The exceptions to this rule are patients born with what we call a covered exstrophy, which is characterized by having both pubic bones separated. These babies are born with no bladder neck, and we believe that they benefit from a permanent closure of the bladder and, subsequently, the creation of a continent diversion. The other exceptions to this rule, as discussed earlier, are patients born with two little hemivaginas and a rectum attached at the bladder neck. When these structures are separated from the urinary tract, there is no bladder neck left. The remaining patients are born with a good bladder neck, and that is a great advantage for them. The type of bladder malfunction that these patients suffer from is not like that observed in spina bifida patients. In other words, we do not see the typical 'christmas tree' type of hypertonic bladder, but rather a floppy smooth wall, atonic bladder with different degrees of incapacity to empty. The combination of a floppy hypotonic bladder with a good bladder neck makes these patients ideal candidates for intermittent catheterization. Forty-seven of our patients (24%) remain dry of urine by emptying the bladder this way.

Bowel control depends mainly on the height of the rectum and also on the characteristics of the sacrum. We have never seen a patient faecally continent with a sacral ratio less than 0.3. The results we achieved in terms of bowel control are shown in Table 2. All patients older than 3 years, followed by us and suffering from faecal incontinence (lack of VBM), remain artificially clean by the implementation of a bowel-management programme.<sup>9</sup>

The presence of tethered cord that occurs in 34% of our patients is associated with poor bowel control, but we do not know the specific impact of this anomaly on bowel and urinary control.

## References

1. Rosen NG, Hong AR, Soffer SZ et al. Recto-vaginal fistula: a common diagnostic error with significant consequences in girls with anorectal malformations. *J Pediatr Surg* 2002; 37:961-5.
2. Gross GW, Wolfson PJ, Peña A. Augmented-pressure colostogram in imperforate anus with fistula. *Radiology* 1991; 21:560-2.
3. Peña A. Persistent cloacas. Atlas of the surgical management of anorectal malformations. New York: Springer 1990 p. 59-71.

4. Peña A. Total urogenital mobilization—an easier way to repair cloacas. *J Pediatr Surg* 1997;**32**:263–8.
5. Peña A. Pediatric surgical problems. In: Corman ML, editor. Colon and rectal surgery. Philadelphia: Lippincott-Raven 1990;449–88.
6. Mitrofanoff P. Cystostomie continente trans-appendiculaire dans le traitement des vessies neurologiques. *Chir Pediatr* 1980;297.
7. Sumfest JM, Burns MW, Mitchell ME. The Mitrofanoff principle in urinary reconstruction. *J Urol* 1993;**150**:1875–7, discussion, p. 1877–8.
8. Levitt MA, Stein DM, Peña A. Gynecological concerns in the treatment of teenagers with cloaca. *J Pediatr Surg* 1998;**33**:188–93.
9. Peña A, Guardino K, Tovilla JM et al. Bowel management for fecal incontinence in patients with anorectal malformations. *J Pediatr Surg* 1998;**33**:133–7.

Available online at [www.sciencedirect.com](http://www.sciencedirect.com)

