



The use of small intestine submucosa in the repair of paraesophageal hernias: Initial observations of a new technique

Brant K. Oelschlager, M.D.*, Marco Barreca, M.D., Lily Chang, M.D.,
Carlos A. Pellegrini, M.D.

The Swallowing Center and Department of Surgery, University of Washington Medical Center, Department of Surgery, 1959 NE Pacific St., Box 356410, Seattle, WA 98195-6410, USA

Manuscript received March 15, 2002; revised manuscript August 12, 2002

Presented at the 89th Annual Meeting of the North Pacific Surgical Association, Seattle, Washington, November 8–9, 2002

Abstract

Background: Recent reports suggest that when laparoscopy is used to repair paraesophageal hernias recurrence rates reach 20% to 40%. Tension-free hernia closure with synthetic mesh reduces recurrence but occasionally results in esophageal injury. We hypothesized that reinforcement of the hiatal closure with small intestine submucosa (SIS) mesh, in some unusually large hernias, might reduce recurrence rates without causing injury to the esophagus.

Methods: From January 2001 to March 2002 we treated 18 large paraesophageal hernias via a laparoscopic approach. In 9 of the largest hernias (one type II and 8 type III, of which 1 was recurrent) the repair was reinforced with SIS mesh (Surgisis, Cook Surgical) and represent the subjects of this study. Nissen fundoplication with gastropexy was performed in all patients. Clinical follow-up ranged from 3 to 16 months (median 8). Every patient was evaluated with barium esophagram or endoscopy or both 1 to 8 months (median 2) postoperatively.

Results: The presenting symptoms were postprandial pain/fullness (9 of 9), heartburn (4 of 9), anemia (4 of 9), dysphagia (3 of 9), regurgitation (3 of 9), and chest pain (3 of 9). One patient died of a hemorrhagic stroke within 30 days of the operation. Postoperatively, presenting symptoms resolved (83%) or improved (17%) in each of the remaining 8 patients. One patient required endoscopic dilation for mild dysphagia. Seven of 8 patients had a normal barium esophagram without evidence of hernia. One morbidly obese (body mass index = 47) patient had a small (2 cm) sliding hiatal hernia postoperatively. There were no other complications, and specifically no perforations or mesh erosions.

Conclusions: These observations suggest that the use of SIS in the repair of paraesophageal hernias is safe and may reduce recurrence. Longer follow-up and a randomized study are needed to validate these results. © 2003 Excerpta Medica, Inc. All rights reserved.

Keywords: Hiatal hernia; Paraesophageal hernia; Small intestinal submucosa; Nissen fundoplication; Prosthesis; Paraesophageal hernia repair

Paraesophageal hernias, unlike sliding hiatal hernias, are a significant cause of morbidity and mortality, and many require surgical repair. The traditional approach has been through a laparotomy or thoracotomy, but over the last decade the laparoscopic approach has been used with greater frequency. The fact that the laparoscopic approach is associated with less pain, a shorter hospital stay, and a faster recovery are arguably very important in these patients since the great majority are elderly. However, recent reports have raised concerns regarding a higher recurrence rate after

laparoscopic repair when compared with open approaches, and have brought into question the ultimate benefit of using this approach [1,2]

Like most hernias, successful repair depends on the integrity of the tissue and the tension needed to approximate it. Therefore, many have advocated the use of a tension free mesh repair, as is used for other types of hernia repairs. Because the use of synthetic mesh is associated with complications such as esophageal stricture, erosion, and perforation most surgeons are reluctant to use them [3,4], thus accepting a higher recurrence rate. A new type of mesh made from porcine small intestine submucosa (SIS) is now available to repair tissue defects. The material serves as a temporary lattice for tissue ingrowth, leading to a strong

* Corresponding author. Tel.: +1-206-543-3518; fax: +1-206-543-8136.

E-mail address: brant@u.washington.edu

tissue matrix, an ideal situation to permanently close a large hiatal defect. Because it is very pliable, not synthetic, and is resorbed in 6 to 12 months, it should be less likely to cause esophageal injury. We, therefore, developed a technique for using SIS to reinforce paraesophageal hernia repair laparoscopically. This report discusses the technique, its safety, and the short-term outcomes of this approach.

Methods

From January 2001 to March 2002 we performed a laparoscopic repair in 18 patients with a symptomatic paraesophageal hernia. Nine of these were especially difficult to repair, requiring significant tension. In these 9 patients, the repair was reinforced with SIS (Surgisis; Cook Surgical, Indianapolis, Indiana). One of these patients had a type II and 8 patients had type III hernias. One of these 9 patients had a previous paraesophageal hernia repair, and had presented with a recurrence. Clinical follow-up ranged from 3 to 16 months (median 8). Each patient was evaluated with barium esophagram or endoscopy or both 1 to 8 months (median 2) postoperatively.

Description of technique

Our standard approach to the repair of paraesophageal hernias was performed in all patients [5]. The short gastric vessels were divided and the entire hernia sac reduced into the abdomen, essentially remaining “hanging” from the gastroesophageal junction. The hernia sac was resected as much as possible avoiding injury to the anterior and posterior vagus and their branches. The esophagus was mobilized until there were at least 3 cm of intraabdominal esophagus without tension. The hiatus was closed posteriorly by approximating the right and left crus with interrupted 2-0 silk sutures. A piece of 7 × 10 cm four-ply Surgisis mesh was fashioned as a keyhole early in our experience, and then changed to a U-shaped configuration. This was done so that the mesh completely covered the crural repair. The mesh was secured to the diaphragm with interrupted silk sutures (Fig. 1). A Nissen fundoplication was then performed. As is our routine, we attached the top of the fundoplication to the undersurface of the diaphragmatic hiatus (and mesh) in at least four places.

Results

The median age of these 9 patients was 63 years (range 47 to 80). The most common presenting symptoms were postprandial pain/fullness (9 of 9), heartburn (4 of 9), anemia (4 of 9), dysphagia (3 of 9), regurgitation (3 of 9), and chest pain (3 of 9). One patient died of a hypertensive, hemorrhagic stroke at home after an uneventful recovery. The remaining 8 patients were available for follow-up

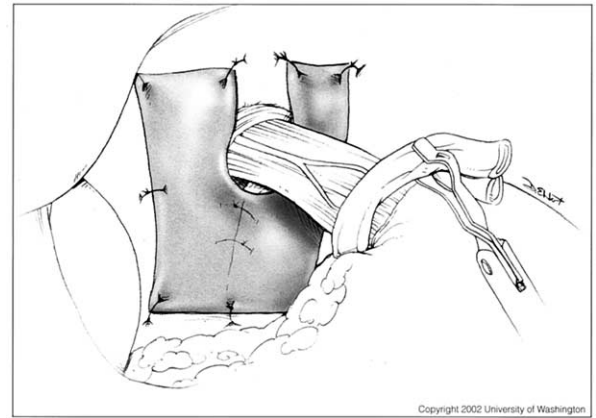


Fig. 1. Placement and fixation of small intestine submucosa mesh in a U-shaped configuration.

The presenting symptoms either resolved (83%) or improved (17%) in each of the 8 patients. One patient had reduced but persistent dysphagia and 3 had mild early satiety initially. All patients were satisfied with the results of their operation.

Seven of 8 patients had a normal postoperative barium esophagram and endoscopy, without evidence of hernia or other abnormality of the cardia (Fig. 2). In 1 patient, the upper gastrointestinal series showed a 2 cm hernia (Fig. 3), which was asymptomatic. The patient was morbidly obese (body mass index = 47) and had required an urgent operation for bleeding. One patient required endoscopic dilation for persistent mild dysphagia (he had no defects in either endoscopy or upper gastrointestinal series). There were no other complications, and specifically no perforations or mesh erosions.

Comments

Paraesophageal hernias have a tendency to recur regardless of the technique used. Indeed, recurrence rates between 12% and 42% have been reported [1,2,6]. Several authors have reported ways to decrease recurrence. They include resection of the sac [7], gastropexy [8], addition of a fundoplication with fixation of the top of the wrap to the undersurface of the diaphragm [9], and the use of thoracotomy to further mobilize the esophagus, resect the sac, and repair the hiatus [1]. Some authors have argued that adding a prosthetic mesh results in a tension free repair, thus decreasing the chances of recurrence [3]. The problem with synthetic materials around the hiatus is that they are known to erode into the esophagus, migrate into the stomach, and cause ulcerations and strictures.

We hypothesized that a new biomaterial, SIS, might provide the surgeon with the ability to effect a reinforced repair, without the potential risks associated with the use of synthetic mesh. Our report, the first of a series of patients treated with this technique, suggests that this is a safe

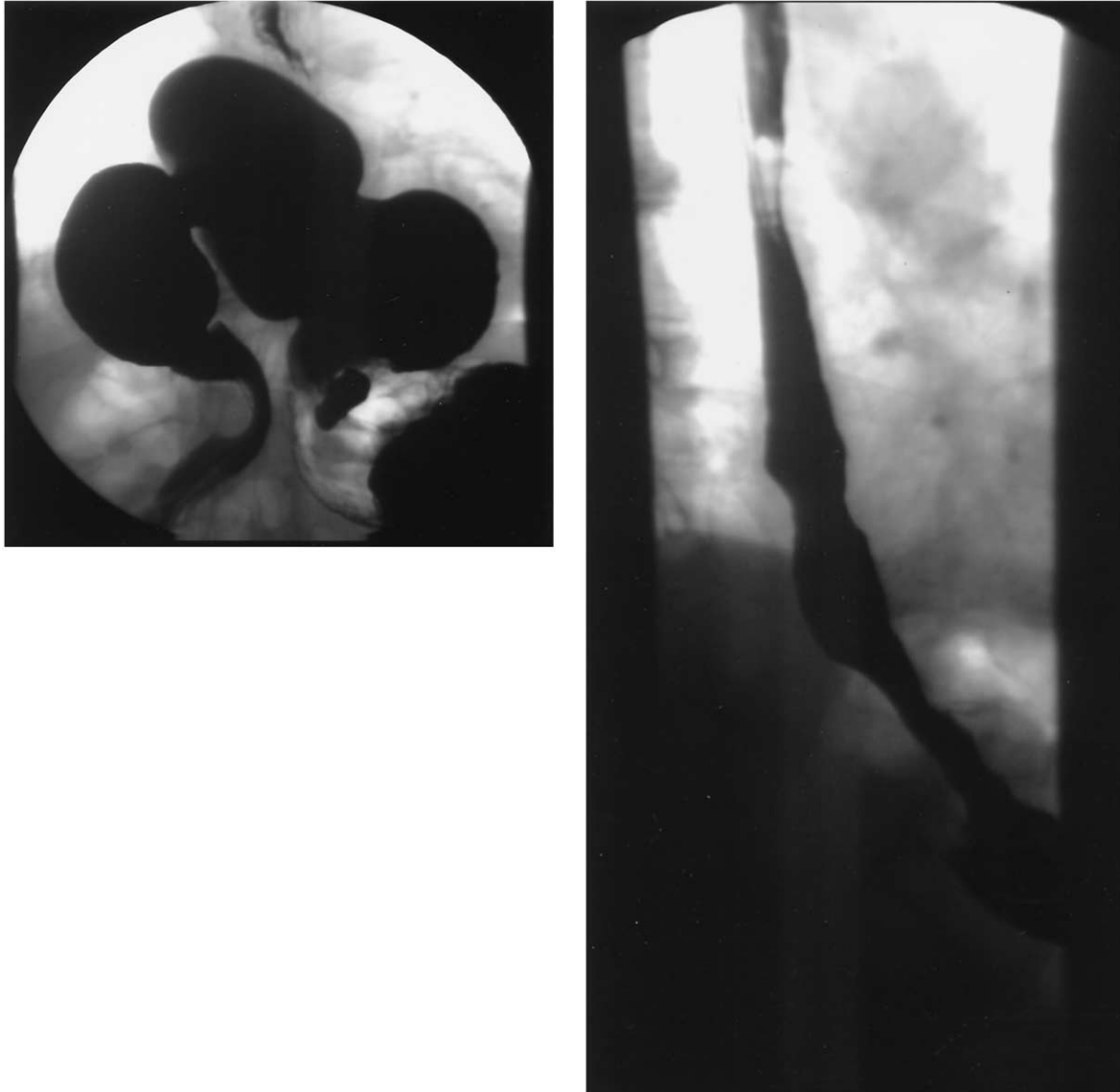


Fig. 2. Typical large paraesophageal hernia before operation. The same patient's follow-up esophagram after laparoscopic repair and small intestine submucosa mesh reinforcement.

method and that symptomatic, radiologic, and endoscopic recurrences are minimized.

Traditionally paraesophageal hernias were repaired by thoracotomy or laparotomy with morbidity of 19% and mortality of 2% [10,11]. With increased experience resulting from operations for gastroesophageal reflux and hiatal hernia, a laparoscopic approach has become more prevalent and appealing. As a result, most series of laparoscopic repairs have reported lower morbidity and mortality than the open techniques [12–14]. In addition, laparoscopy appears to have some of the benefits of both thoracotomy (the hiatus can be accessed easier, the esophagus can be dissected under direct vision) and laparotomy (less morbidity, no need to collapse the lung, no need for postoperative chest tube).

Recently, Hashemi et al [1] reported a much higher

recurrence rate for patients who had had a repair via the laparoscopic approach (42%), when compared with those operated on via thoracotomy and laparotomy (15%). Other groups have found high rates of anatomic recurrences when performing routine esophagram [2]. Although several other studies report recurrence rates from 0% to 4% for laparoscopic repair, the great majority of patients included have not undergone barium esophagrams and the integrity of the repair is judged only on the basis of symptoms [12,15–19]. In fact, the only study that compared open and laparoscopic approaches for the treatment of paraesophageal hernias reported a higher incidence of recurrence in the open repair group (8% versus 0%) [14], but this too was based on symptomatic recurrence and was not randomized.

There are several reasons why simple, direct repair by suturing of the pillars of the crus may not be enough. First,

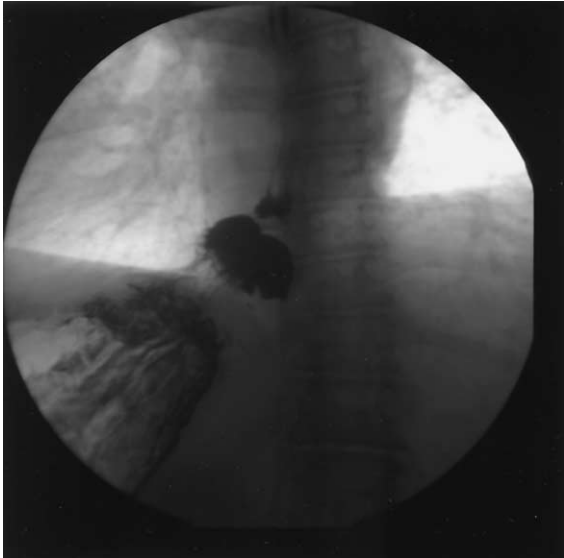


Fig. 3. Small, asymptomatic postoperative sliding hiatal hernia.

the defect from a chronically incarcerated stomach can be quite large. Closing a large defect will be done under considerable tension. Second, the pillars tend to be very thin in these elderly patients and thus the closure approximates attenuated muscle of the diaphragm, not fascia or strong tissue. Third, there are significant episodes of stress on the repair of the diaphragm during cough, Valsalva maneuvers, and even perhaps during regular breathing. With the development and wide application of mesh materials for tension-free repair of inguinal and ventral hernias, many surgeons have applied similar techniques to the hiatus. The use of a mesh certainly facilitates the closure, and has been shown to decrease the recurrence rate [20]. However, the problem lies with the potential for development of esophageal strictures, erosions, and ulcerations because of the movement of this mesh and diaphragm constantly over the outer surface of the esophagus. Indeed, there are examples of significant dysphagia [3] and esophageal erosion [4] in the literature, which can be devastating complications. To avoid this we have in the past used a technique described by Huntington [21], based on a “relaxing” incision made in the middle of the right crus. This allows the rest of the right crus to be sutured to the left, and the resulting defect is “patched” with a piece of synthetic mesh. In practice, however, the right crus is usually very thin, leaving little muscle to bring toward the midline and the mesh is still very close to the esophagus.

Small intestinal submucosa is an acellular xenograft consisting primarily of type I porcine collagen. Experimental evidence suggests that the extracellular matrix scaffolds provided by SIS rapidly degrades, but the tissue remodeling that replaces the matrix is stronger than native tissue [22,23]. Thus, its characteristics appear very conducive for use in paraesophageal hernia repairs. This material has been used around the cardia to reinforce the gastrojejunal anastomosis during Roux-en-y gastric bypass operations for

morbid obesity without complications [24]. There is evidence for using SIS on the diaphragm, where it has been used successfully in the repair of congenital diaphragmatic hernias [25]. There are also reports of its effectiveness for the repair of inguinal hernias [26]. Therefore, the literature to date suggests SIS to be safe around delicate organs (eg, esophagus) and possibly efficacious for repair of the diaphragm and other hernia defects.

Our experience suggests that the laparoscopic repair of paraesophageal hernias with SIS is successful in relieving the presenting symptoms. Most importantly it does not appear that the use of SIS is associated with significant complications. One patient developed mild dysphagia that was effectively relieved with a single endoscopic dilation. Dysphagia is a known complication of Nissen fundoplication [27], so its development in this patient may not necessarily be result of using SIS. It should be noted, however, that this occurred early in our experience when we were placing the mesh in a keyhole fashion. Because of this episode and the findings of some unpublished animal data suggesting some natural constriction of the mesh, we have moved to a U-shaped technique based posteriorly over the crural repair. The only other adverse outcome observed in this study was a patient that died from a hypertensive, hemorrhagic stroke. This patient’s postoperative course was until then unremarkable. The patient was discharged after a 2-day hospitalization with no complications. It is unlikely that this unfortunate event was related to the use of SIS.

The study size, methodology, and short-term follow-up do not allow us to determine whether the use of SIS decreases the rate of recurrence. However, the fact that we used SIS only in our largest hernias, and that the repairs appear to be intact endoscopically and radiographically in these patients is encouraging. Indeed, the only small, asymptomatic defect found on a postoperative barium esophagram was noted in a morbidly obese patient. This patient had a very large hiatus with the majority of the stomach herniated in the mediastinum and had been operated because a strangulation had led to bleeding. Obesity is a risk factor for recurrence after standard antireflux procedures [28]. Though there are no stratified data for paraesophageal hernia repairs in obese patients, the recurrence rate is likely to be higher than in nonobese patients. All other patients had normal upper gastrointestinal studies similar to that shown in Fig. 2B.

In conclusion, the use of SIS in the repair of paraesophageal hernias is a logical extension of the concept of a tension-free repair. The fact that the material is pliable, easy to use, strong, reabsorbable are all characteristics that make it appealing to close the hiatus. The ingrowth of collagen into the lattice of the material provides further support to the hiatus. Our initial observations suggests that the material is easy to use, and appears safe. Short-term follow-up shows that when SIS is used in addition to the traditional maneuvers (resection of the sac, closure of the hiatus and a Nissen fundoplication) symptoms are improved and the recurrence

rate is low. These results should be tested through a prospective, randomized trial.

Acknowledgments

This work was supported in part by the Mary and Dennis Wise Fund and in part by an educational grant from United States Surgical Corporation, Tyco Healthcare.

References

- [1] Hashemi M, Peters JH, DeMeester TR, et al. Laparoscopic repair of large type III hiatal hernia: objective follow-up reveals high recurrence rate. *J Am Coll Surg* 2000;190:554–61.
- [2] Mattar SG, Bowers SP, Galloway KD, et al. Long-term outcome of laparoscopic repair of paraesophageal hernia. *Surg Endosc* 2002;16:745–9.
- [3] Carlson MA, Condon RE, Ludwig KA, Schulte WJ. Management of intrathoracic stomach with polypropylene mesh prosthesis reinforced transabdominal hiatus hernia repair. *J Am Coll Surg* 1998;187:227–30.
- [4] Trus TL, Bax T, Richardson WS, et al. Complications of laparoscopic paraesophageal hernia repair. *J Gastrointest Surg* 1997;1:221–8.
- [5] Casabella F, Sinanan M, Horgan S, Pellegrini CA. Systematic use of gastric fundoplication in laparoscopic repair of paraesophageal hernias. *Am J Surg* 1996;171:485–9.
- [6] Horgan S, Eubanks TR, Jacobsen G, et al. Repair of paraesophageal hernias. *Am J Surg* 1999;177:354–8.
- [7] Edey M, Salky B, Posner A, Fierer A. Sac excision is essential to adequate laparoscopic repair of paraesophageal hernia. *Surg Endosc* 1998;12:1259–63.
- [8] Kercher KW, Matthews BD, Ponsky JL, et al. Minimally invasive management of paraesophageal herniation in the high-risk surgical patient. *Am J Surg* 2001;182:510–14.
- [9] Oelschlager BK, Pellegrini CA. Paraesophageal hernias: open, laparoscopic, or thoracic repair. *Chest Surg Clin North Am* 2001;11:589–603.
- [10] Ellis FH, Crozier RE, Shea JA. Paraesophageal hiatus hernia. *Arch Surg* 1986;121:416–20.
- [11] Pearson FG, Cooper JD, Ilves R, et al. Massive hiatal hernia with incarceration: a report of 53 cases. *Ann Thoracic Surg* 1983;35:45–51.
- [12] Huntington TR. Short-term outcome of laparoscopic paraesophageal hernia repair: a case series of 58 consecutive patients. *Surg Endosc* 1997;11:894–8.
- [13] Jobe BA, Aye RW, Deveney CW, et al. Laparoscopic management of giant type III hiatal hernia and short esophagus: objective follow-up at three years. *J Gastrointest Surg* 2002;6:181–8.
- [14] Schauer PR, Ikramuddin S, McLaughlin RH, et al. Comparison of laparoscopic versus open repair of paraesophageal hernia. *Am J Surg* 1998;176:659–65.
- [15] Edey MB, Canin-Endres J, Gattorno F, Salky BA. Durability of laparoscopic repair of paraesophageal hernia. *Ann Surg* 1998;228:528–35.
- [16] Gantert WA, Patti MG, Arcerito M, et al. Laparoscopic repair of paraesophageal hiatal hernias. *J Am Coll Surg* 1998;186:428–33.
- [17] Krahenbuhl L, Schafer M, Farhadi J, et al. Laparoscopic treatment of large paraesophageal hernia with totally intrathoracic stomach. *J Am Coll Surg* 1998;187:231–7.
- [18] Myers GA, Harms BA, Starling JR. Management of paraesophageal hernia with a selective approach to antireflux surgery. *Am J Surg* 1995;170:375–80.
- [19] Perdakis G, Hinder RA, Filipi CJ, et al. Laparoscopic paraesophageal hernia repair. *Arch Surg* 1997;132:586–90.
- [20] Frantzides CT, Madan AK, Carlson MA, Stavropoulos GP. A prospective, randomized trial of laparoscopic polytetrafluoroethylene (PTFE) patch repair vs simple cruroplasty for large hiatal hernia. *Arch Surg* 2002;137:649–52.
- [21] Huntington TR. Laparoscopic mesh repair of the esophageal hiatus. *J Am Coll Surg* 1997;184:399–400.
- [22] Baylak S, Kokini K, Tullius B, Whitson B. Strength over time of a resorbable bioscaffold for body wall repair in a dog model. *J Surg Res* 2001;99:282–7.
- [23] Gloecker DC, Sacks MS, Billiar KL, Bachrach N. Mechanical evaluation and design of a multilayered collagenous repair biomaterial. *J Biomed Mater Res* 2000;52:365–73.
- [24] Kini S, Gagner M, de Csepel J, et al. A biodegradable membrane from porcine intestinal submucosa to reinforce the gastrojejunostomy in laparoscopic Roux-en-y gastric bypass: preliminary report. *Obes Surg* 2001;11:469–73.
- [25] Vecchia LD, Engum S, Kogon B, et al. Evaluation of small intestine submucosa and acellular dermis as diaphragmatic prostheses. *J Pediatr Surg* 1999;34:167–71.
- [26] Edelman DS. Laparoscopic herniorrhaphy with porcine small intestinal submucosa: a preliminary study. *J Surg Laparosc Surg* 2002;6:203–5.
- [27] Carlson MA, Frantzides CT. Complications and results of primarily invasive antireflux procedures: a review of 10,735 reported cases. *J Am Coll Surg* 2001;193:428–39.
- [28] Perez AR, Moncure AC, Rattner DW. Obesity adversely affects the outcome of antireflux operations. *Surg Endosc* 2001;15:986–9.