



## Cloacal malformations: lessons learned from 490 cases

Marc A. Levitt, MD, Alberto Peña, MD

*From the Division of Pediatric Surgery, Colorectal Center for Children, Cincinnati Children's Hospital Medical Center, University of Cincinnati College of Medicine, Cincinnati, Ohio.*

### KEYWORDS

Cloaca;  
Anorectal  
malformation;  
Urogenital  
mobilization;  
Vaginal replacement

In this review we describe lessons learned from the authors' series of patients born with the most complex of congenital anorectal problems, cloacal malformations, with the hope to convey the improved understanding and surgical treatment of the condition's wide spectrum of complexity learned from patients cared for over the last 25 years. This includes a series of 490 patients, 397 of whom underwent primary operations, and 93 who underwent reoperations after attempted repairs at other institutions. With regard to the newborn, we have learned that the clinician must make an accurate neonatal diagnosis, drain a hydrocolpos when present, and create an adequate, totally diverting colostomy, leaving enough distal colon available for the pull-through, and a vaginal replacement if needed. A correct diagnosis will avoid repairing only the rectal component. For the definitive reconstruction, all patients in the series were managed with a posterior sagittal approach; 184 of whom also required a laparotomy. The average length of the common channel was 4.6 cm for patients who required a laparotomy and 2.5 cm for those who did not. Hydrocolpos was present in 139 patients (30%). Vaginal reconstruction involved a vaginal pull-through in 308 patients, a vaginal flap in 44, vaginal switch in 48, and vaginal replacement in 90 (33 with rectum, 15 with colon, and 42 with small bowel). A total of 220 underwent total urogenital mobilization, which was first introduced in 1996. Complications included rectal prolapse in 26, vaginal stricture or atresia in 18, urethrovaginal fistula in 13, and urethral atresia in 6. A total of 53% of all cases have voluntary bowel movements. The others are kept clean with a mechanical daily emptying (an enema) as part of a bowel management program. Indications for reoperations included persistent urogenital sinus after initial repair in 39 patients. Fifty-one had problems such as rectal prolapse, stricture, retraction, dehiscence or atresia, 29 had a mislocated rectum, 34 had vaginal stricture, retraction, dehiscence, atresia, or stenosis, 16 had urethrovaginal or rectovaginal fistulae, and 5 had urethral stricture or atresia. The series was divided into 2 distinct groups of patients where common channel measurement was known (n = 400): group A were those with a common channel  $\leq 3.0$  cm (n = 225, 56%) and group B had a common channel  $> 3$  cm (n = 175, 44%). The separation into these 2 groups has important therapeutic and prognostic implications. Patients in Group A can be repaired posteriorly with a reproducible operation. Because they represent most patients, most well-trained pediatric surgeons should be able to repair these types of malformations, and the prognosis is good. Patients in Group B (those with a common channel  $> 3$  cm), usually require a laparotomy, have a much higher incidence of associated urological problems, and often require special maneuvers for vaginal reconstruction. Surgeons who repair Group B malformations require special training in urology; the operations are prolonged and technically demanding, and the functional results are not as good as in group A.

© 2010 Elsevier Inc. All rights reserved.

---

**Address reprint requests and correspondence:** Marc A. Levitt, MD, Division of Pediatric Surgery, Colorectal Center for Children, Cincinnati Children's Hospital Medical Center, University of Cincinnati College of Medicine, 3333 Burnet Avenue MLC 2023, Cincinnati, OH 45229.  
E-mail address: [Marc.levitt@cchmc.org](mailto:Marc.levitt@cchmc.org).

In a cloaca, the vagina, urethra, and rectum are fused together inside the pelvis, creating a common channel that opens into a single orifice at the position where the urethral opening is normally located. Cloacae represent a wide spectrum of defects, but the common denominator is the presence of a single perineal orifice. On the more severe side of the

**Figure 1** Most of the patients with hydrocolpos also have duplicate Mullerian systems. (Reprinted from Peña A. Atlas of surgical management of anorectal malformations; with permission from Springer Verlag.)

spectrum, one may find patients with a common channel >5 cm. The length of the common channel varies from 1-10 cm, with an average of approximately 3 cm.

A total of 30% of these patients have a very dilated vagina filled with fluid, urine, and/or mucus, called hydrocolpos.<sup>1,2</sup> The reason why the dilated vagina retains fluid is a mystery, as the common channel is almost never atretic. Likely there is a valve mechanism that interferes with emptying of the fluid. Most of the patients with hydrocolpos also have a duplicate Mullerian system (Figure 1).

The hydrocolpos may produce 2 important complications; first it may compress the trigone of the bladder, producing ureterovesical obstruction, megaureter, and hydronephrosis (Figure 2), and second, the hydrocolpos if left undrained may become infected, leading to a pyocolpos that eventually may perforate. The resulting inflammation may scar the vagina and affect the future reconstruction.

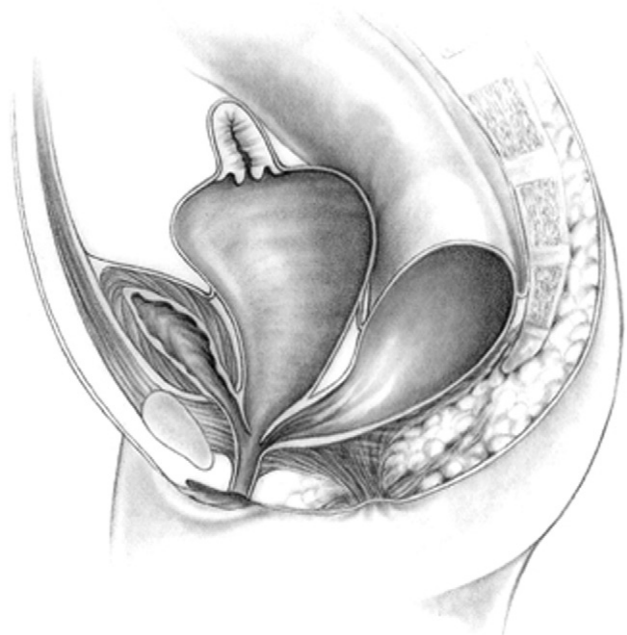
Approximately 40% of patients have a double Mullerian system consisting of 2 hemiuteri and 2 hemivaginas. This septation disorder may be partial or total and symmetric or asymmetric (Figure 1). In the asymmetric type, the double Mullerian system phenomenon is frequently associated with a unilateral atresia of the Mullerian structure. When this goes unrecognized, it may produce an accumulation of menstrual blood at the age of puberty, as well as retrograde menstruation into the peritoneal cavity. The presence of double Mullerian systems also has important obstetrical implications.<sup>3</sup>

Associated defects are common. Most vital to recognize are the urological abnormalities which include absent kidney, vesicoureteral reflux, horseshoe kidney, ectopic ureters, double ureters, hydronephrosis, and megaureters as a result of vesicoureteral reflux or ureterovesical obstruction.

Treatment of cloacas represents a significant technical challenge, with the goals that a patient should have urinary control, bowel control, sexual function, and obstetrical potential. These goals, of course, are sometimes achieved, and sometimes partially achieved. Even for the most severe cases, we are firm in our philosophy that all patients with anorectal and urogenital malformations should be clean of stool in the underwear and dry of urine after the age of 3; these patients were either born with a benign malformation that was adequately reconstructed allowing them to realize their continence potential, or were born with a malformation with a bad functional prognosis, but can be maintained artificially clean of stool (subjected to a successful bowel management program) and dry of urine (subjected to intermittent catheterization) through the native urethra or through a neourethra (continent diversion).

## Neonatal management

The diagnosis of a cloaca is a clinical one made by identifying a single perineal orifice. The perineum has other important characteristics that help predict the internal anatomy and the final functional prognosis. A “good-looking” perineum consists of a well-formed midline groove and a well-located and clear anal dimple, indicating that the patient has a good sphincter. A “bad-looking” perineum has a single perineal orifice but in addition, a “flat bottom,” with no traces of a sphincter mechanism and most likely, a poor



**Figure 2** The hydrocolpos may compress the trigone of the bladder, producing ureterovesical obstruction, megaureter, and hydronephrosis. (Reprinted from Peña A. Atlas of surgical management of anorectal malformations; with permission from Springer Verlag.)

functional prognosis. Sometimes one finds hypertrophic folds of skin in the area of the single perineal orifice, which gives a false impression of a phallus which is likely why some patients are misdiagnosed with disorders of sexual development.

The first 24 hours after birth, like in all other babies with an anorectal malformation, should be used to rule out the presence of associated problems that may represent a risk to life.<sup>1</sup> The most important one, in patients with a cloaca, is urinary tract obstruction. The baby must have a kidney and bladder ultrasound study to rule out the presence of hydronephrosis and megaureters and also a pelvic ultrasound to evaluate for the presence of hydrocolpos. A plain abdominal radiograph in a baby with a single perineal orifice may show an image of a pelvic mass, which most likely represents a hydrocolpos that must be drained soon. An ultrasound study that shows hydronephrosis, megaureter, and a cystic pelvic mass, most likely represents a hydrocolpos that is compressing the trigone of the bladder and is causing the bilateral megaureters and the hydronephrosis.

Hydrocolpos as a cause of megaureter and hydronephrosis often goes unrecognized.<sup>2</sup> Patients with hydronephrosis and megaureter may be subjected to an unnecessary and unindicated ureterostomy, vesicostomy, and/or nephrostomy. Most of the time, drainage of the hydrocolpos alone takes care of the problem of megaureter and hydronephrosis. Only in those patients who have, in addition, vesicoureteral reflux and difficulty emptying their bladder, often due to a long and narrow common channel, does vaginostomy alone not help, and a vesicostomy is needed. If the patient has a hydrocolpos, the first step should be drainage of the hydrocolpos prior to making decisions concerning any urological procedures.

An echocardiogram should be done to rule out cardiac conditions, esophageal atresia must be ruled out with passage of a nasogastric tube, and a spinal ultrasound is indicated to evaluate for the presence of tethered cord. A plain abdominal radiograph will show the characteristics of the lumbar and thoracic spine as well as the sacrum, and a sacral ratio can be calculated.

Babies with a cloaca need a colostomy, and a descending colostomy with a tiny mucous fistula completely separated from the proximal stoma is ideal. The patient must be left with a good length of distal colon long enough for the future pull-through, and even for a vaginal replacement if needed. We are strongly opposed to the opening of loop colostomies in these babies, because that type of stoma frequently allows the passage of stool into the distal bowel with direct fecal contamination of the urinary tract. If the patient has evidence of hydrocolpos, the surgeon must drain it at the same time, which is best done with a pigtail catheter that is exteriorized through one of the lower quadrants. (A curled catheter is less likely to fall out during the initial several months of life when the inflammation recedes and the vagina moves away from the abdominal wall.) Because most of the patients with hydrocolpos have bilateral hydrocolpos,

a window is needed in the septum between the 2 hemivaginas to use a single tube to drain both.

A newborn with a cloaca that has a colostomy and is not doing well postoperatively usually has an undrained obstructed urinary tract, with or without hydrocolpos. Therefore, the first study in such patients should be an ultrasound which can evaluate for hydronephrosis, megaureter, a large bladder, or hydrocolpos, or, in the case of a loop stoma or if both stomas are being bagged together, distal stool spillage may lead to urinary tract infection.

When the patient is well treated, the colostomy is adequate, and the urinary tract and hydrocolpos are well drained, recovery is rapid. The patients can go home and within several months will be ready for the main repair.

## Definitive reconstruction

Before 1982, the primary surgical treatment of cloacas was not performed with a systematic approach. The related publications were few, with rather poor descriptions of improvised types of operations. Dr Hardy Hendren made significant contributions to the surgical repair of patients born with cloacas.<sup>4</sup> He initially referred to these defects as "imperforate anus with urogenital sinus."<sup>5</sup> His main contributions in cloacal management were in secondary operations and in methods to deal with the myriad urological problems.

In June 1982, the posterior sagittal approach was used by the senior author for the first time to repair a cloaca.<sup>6</sup> Fortuitous at the time, that first cloaca was what we now consider a "benign type" of malformation, meaning that the common channel was relatively short (<3 cm) and therefore it was able to be repaired. That patient today has urinary control, bowel control, sexual function, and subsequently has successfully delivered a baby by cesarean section.

During the first few years after 1982, the approach for the repair of cloacas, the posterior sagittal anorectovaginourethroplasty, consisted of separating the rectum from the urogenital tract like in all other malformations, followed by the separation of the vagina from the urethra and bladder, reconstruction of the common channel as a neo-urethra, mobilization and dissection of the vagina so that it could be pulled down to be placed posterior to the urethra, and performance of a pull-through of the rectum placing it within the limits of the sphincter. That approach was highly successful in a certain type of cloaca that we now refer to as "benign," but was not successful in more complex types.

The main lesson learned during the last 3 decades, in managing nearly 500 cases, is that cloacal malformations represent a broad spectrum of defects. It has been an eye-opening, constant learning experience. The more experience we develop, the more we understand that the spectrum seems to be wider and wider. This learning process has allowed the design of surgical maneuvers applicable to different anatomical variants of these defects, which we will describe in this review.

In 1996, for the first time, the senior author used an innovative surgical maneuver called, “Total Urogenital Mobilization,” which dramatically reduced operative time and lead to better cosmetic and functional results.<sup>7</sup> Total urogenital mobilization often is not enough to repair more complex types of defects and, therefore, a “Transabdominal Extended Total Urogenital Mobilization procedure,” is needed, which allows for the repair of cloacas with common channels of 3-5 cm. Yet, even with the use of an “extended transabdominal” approach, some cloacas require further technically demanding maneuvers, including the complete separation of bladder and urethra from the genital tract. To do that, the bladder must be opened and feeding tubes passed into the ureters to help avoid injury to them. In addition, in some patients, we need to carve the pubic cartilage to create a shorter trajectory for the urethra and vagina so they can be pulled down behind the pubis and sutured next to the clitoris. In some cases, a maneuver called the “Vaginal Switch” is needed. In another group of cases, we have totally or partially replaced the vagina with rectum, colon, or small bowel. Finally, there is a group of cloacas with an extremely long common channel (>5 cm), in whom the common channel is left intact and can become the neourethra, and later be used as a conduit for intermittent catheterization. For such cases, we start with a laparotomy to separate the vagina(s) and the rectum from the trigone or the bladder neck.

As we learned more about the complexity of cloacal malformations, we developed a serious concern about the reproducibility of some of the techniques used to repair them. However, more than 50% of cloacas have a common channel <3 cm.<sup>8</sup> This means that they can be repaired by means of a posterior sagittal approach, using the “Total Urogenital Mobilization” without opening the abdomen, a reproducible maneuver which can be learned by most pediatric surgeons. By contrast, cases with a common channel >3 cm have a much more involved reconstruction and should be repaired by those specially dedicated and experienced in dealing with cloacas (Tables 1 and 2).

Figure 3 shows our decision-making algorithm in the repair of cloacas. Before surgery, we review a contrast study of the cloaca which now can be done in 3-D<sup>9</sup> (Figure 4). We strongly recommend that the general pediatric surgeon do the vaginoscopy and cystoscopy in a separate setting outside of the newborn period. With endoscopy and a cloacagram the general pediatric surgeon will be able to:

**Table 1** Cloaca common channel lengths

Common channel length	No. patients
1 cm or less	43
1-3 cm	182
3-5 cm	128
>5 cm	47
Common channel not known	90
Total	490

**Table 2** Two major groups of cloacas

	Group A	Group B
Common channel	Short, <3 cm	Long, >3 cm
Type of operation	Only posterior sagittal	Posterior sagittal and laparotomy
Length of procedure	3 hours	6-12 hours
Postoperative hospitalization	48 hours	Several days
Incidence in our series	56% (n = 225)	44% (n = 175)
Voluntary bowel movements	66%	36%
Urinary continence	74%	28%
Intraoperative decision-making	Relatively easy, reproducible operation	Complex, delicate, and technically demanding*

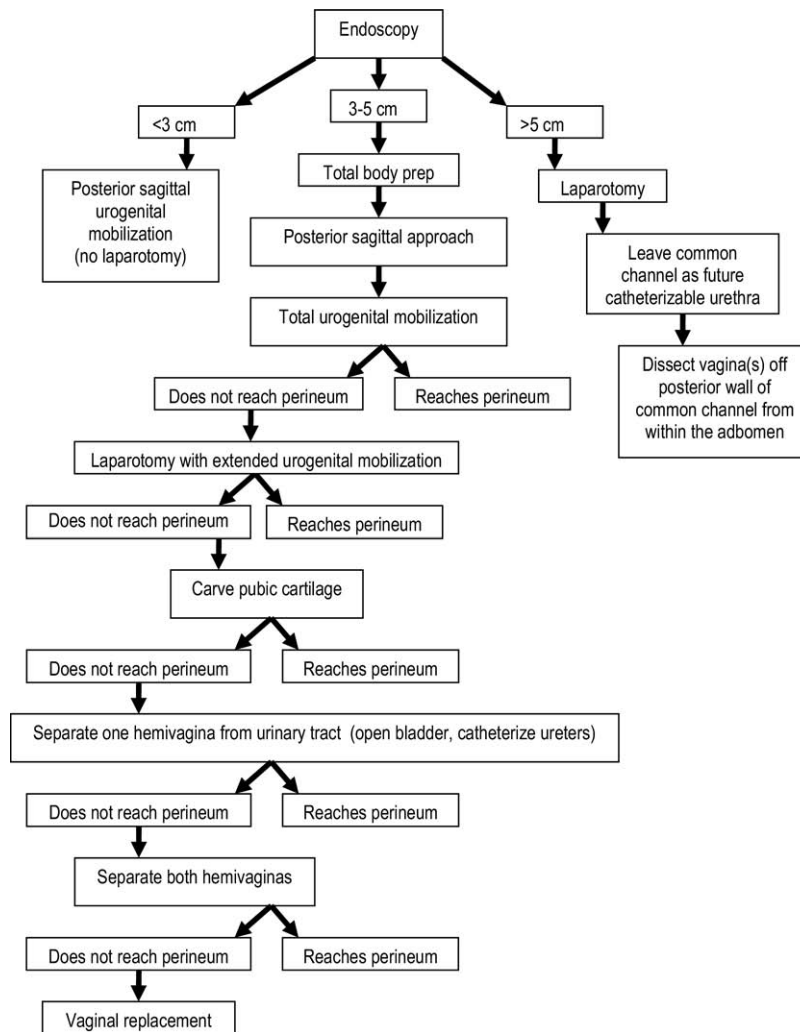
\*Bladder/vagina separation, ureteral catheterization, vesicostomy, bladder neck reconstruction or closure, vaginal switch, vaginal replacement (with rectum, colon, or small bowel).

- determine whether they can perform the operation or whether the patient should be referred to a specialized center,
- determine whether it will be necessary to open the abdomen for the reconstruction. This represents important information for the anesthesiologist and the entire operating team. It helps with equipment needs, predicting operating time, etc,
- predict the functional prognosis, and
- determine whether the patient needs a bowel preparation, and whether vaginal replacement with bowel is likely to be necessary.

## Subtypes of cloacal malformations

### Cloacas with a common channel 1 cm or less (n = 43)

In instances of very short common channel cloaca, we recommend a relatively straightforward procedure that we call a posterior sagittal anorectal vaginoplasty. The urethra is left untouched. We separate the rectum from the vagina as in cases of vestibular fistulas, then, rather than separating the vagina from the urinary tract or performing a total urogenital mobilization, we mobilize only the lateral and posterior walls of the vagina, enough to be able to suture the edges of the vagina to the skin of the neolabia. In this manner, we avoid disturbing the urethra or the common wall between the vagina and urethra. The cosmetic effect of this operation is excellent. The results in terms of bowel and urinary control are similar to those of patients with recto-vestibular fistula and are excellent when the sacrum and spine are normal. These patients may be left with a mild female hypospadias, which is irrelevant because they do not



**Figure 3** Algorithm for the surgical reconstruction of a cloaca.

need intermittent catheterization and because the urethral meatus is readily visible.

### Cloacas with a 1-3 cm common channel (n = 182)

Most cloacas are of this type (Figure 5). These patients have, in general, a good prognosis. Less than 20% of them require intermittent catheterization after reconstruction. Bowel function depends on the quality of the sacrum and spine.

We repair these malformations any time from 1 to 12 months of age, and ideally, if the baby is growing and developing normally, between 1 and 3 months of life. Most of our patients, however, come from other institutions and, therefore, we have experience doing this procedure at different ages.

When the 3D cloacagram (Figure 4), vaginoscopy, and cystoscopy show that the patient has a common channel of 1-3 cm, we can be confident that we can repair that malformation using only the posterior sagittal approach with total urogenital mobilization, without opening the abdomen. The

operation takes approximately 3 hours. The cosmetic and functional result is excellent.

The patient is placed in prone position, with the pelvis elevated. A posterior sagittal incision is used, running from the lower portion of the sacrum down to the single perineal orifice. We divide the skin, subcutaneous tissue, parasagittal fibers, and the entire sphincter mechanism precisely in the midline. The common channel is opened exactly in the midline which exposes the internal anatomy of the malformation. Placing a mosquito clamp in the single perineal orifice helps guide the midline incision of the posterior aspect of the common channel.

The first step, as in all cloacas, consists of separating the rectum from the vagina. When the patient has 2 Mullerian systems, the rectum is found in the middle of both hemivaginas, opening usually in a little orifice located in the posterior aspect of the vaginal septum. Multiple 5.0 silk stitches are placed around the rectal opening to apply uniform traction. Special emphasis is placed on creating a plane of dissection in the common wall between the rectum and the vagina(s). After the rectum and vagina(s) are fully sepa-

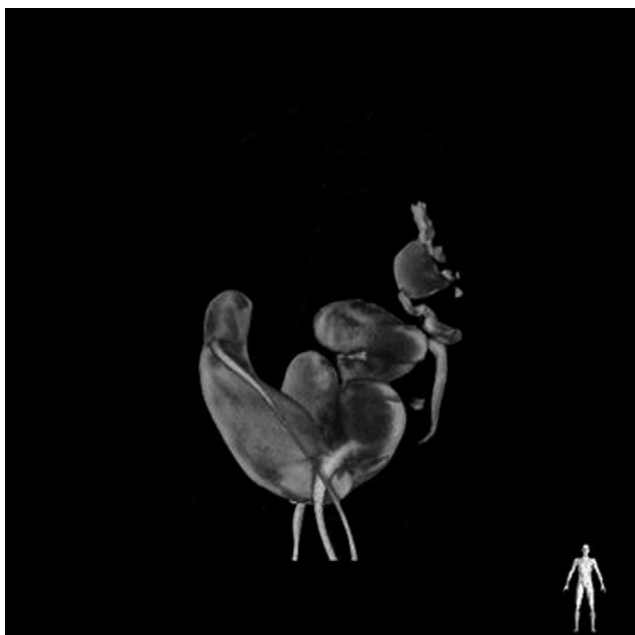

Figure 4 3-D Cloacagram.

rated, a circumferential dissection is performed, dividing the bands and vessels that hold the rectum in the pelvis. As we progress with this dissection, we keep gaining length until we have enough rectum to comfortably reach the perineum to be able to place it within the limits of the sphincter.

Before 1996, the vagina was separated from the urinary tract,<sup>6</sup> which was a technically demanding maneuver, took many hours, and led to a significant number of urethrovaginal fistulas because of that separation<sup>8</sup> in 1996, the total urogenital mobilization was utilized<sup>7</sup> (Figure 6). For this, we place multiple 5.0 silk sutures in the edges of the common channel and the lateral walls of the vagina to apply

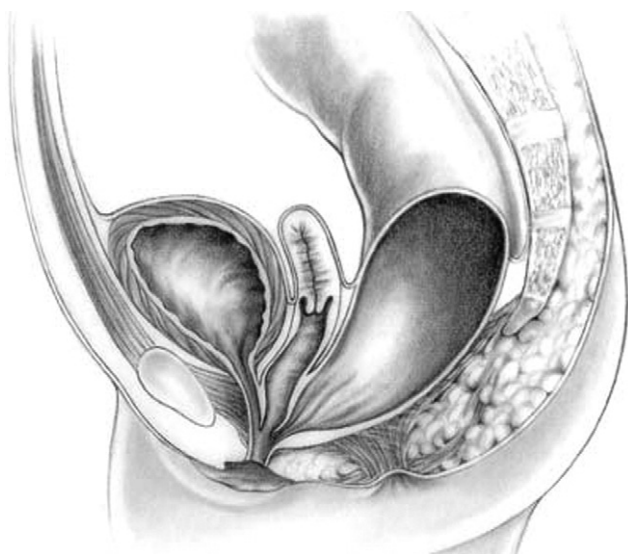


Figure 5 Cloaca with a short common channel. (Reprinted from Peña A. Atlas of surgical management of anorectal malformations; with permission from Springer Verlag.)

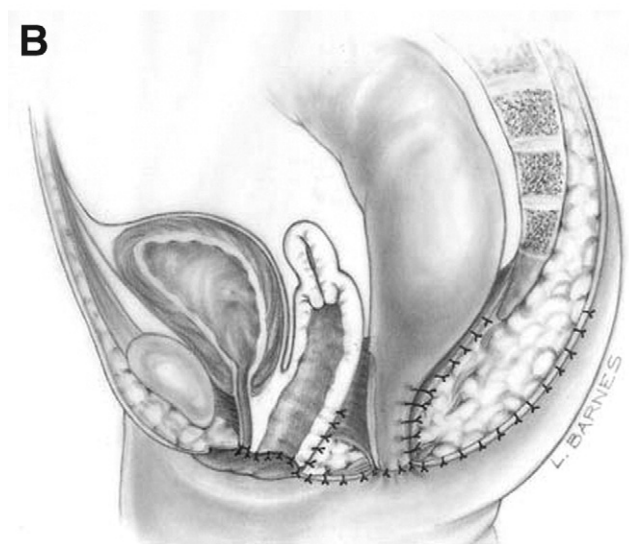
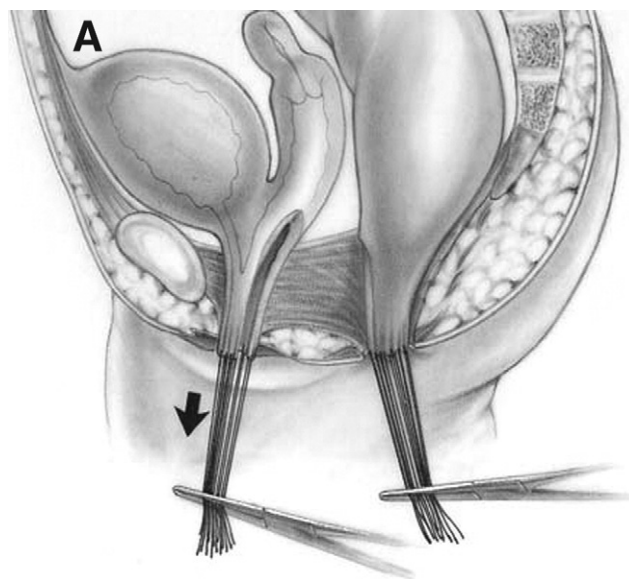


Figure 6 (A, B) Total urogenital mobilization. (Reprinted with permission.<sup>7</sup>)

uniform traction. Another set of sutures is placed in a horizontal, transverse manner, about 5 mm above the clitoris. The common channel is divided distal to the transverse line of sutures between the clitoris and the sutures using the needle tip cautery. The incision includes the full thickness of the common channel. A plane of dissection exists between the pubis and the common channel. The suspensory ligaments of the urethra are visualized and divided with cautery as well as their lateral attachments on both sides of the vagina. When these suspensory ligaments of the vagina and urethra are divided, one sees a characteristic retropubic fat pad. These ligaments extend onto both lateral walls of the vagina and must be divided, with preservation of the blood supply of the vagina. By dividing them, we gain approximately 2 cm of length in the common channel. We then go to the posterior part of the vagina(s) and divide the bands found posterior and laterally, which gains another

centimeter. As a consequence, in most instances, the total urogenital mobilization allows for the mobilization of the vagina and urethra with a common channel of 3 cm. Occasionally, cloacas with a 4-5 cm common channel can be repaired using this posterior sagittal maneuver.

After we mobilize the urogenital sinus, we then split the common channel in the midline, into 2 lateral flaps. By doing this, we can suture the urethral meatus to the tissue behind the clitoris. The 2 flaps developed from what used to be the common channel, now become part of the neolabia. The lateral walls of the vagina(s) are sutured to the neolabia and a normal-looking introitus is created. The electrical stimulator is then used to determine the limits of the anal sphincter. The perineal body is reconstructed between the posterior limit of the vagina and the anterior limit of the sphincter. The rectum is then placed within the limits of the sphincter and in front of the levator mechanism.

### **Cloacas with a 3-5 cm common channel (n = 128)**

When the contrast study and the endoscopy demonstrate that the patient has a common channel length of 3-5 cm, we perform a total body preparation because we know that it will most likely be necessary to open the abdomen, in addition to using the posterior sagittal approach, to repair the malformation. The operation begins with the patient in the prone position and pelvis elevated. With a posterior sagittal incision, the internal anatomy of the malformation is exposed; the rectum is separated from the urogenital tract, and a total urogenital mobilization is performed, as described previously. Occasionally, we are happily surprised to find that it is possible to reconstruct the urethra, vagina, and rectum without opening the abdomen. However, most of the time, total urogenital mobilization is not enough to repair the malformation. In such cases, the patient is turned to the supine position and the abdomen is opened with a midline infraumbilical incision.

We then perform what we call an "Extended Transabdominal Urogenital Mobilization." Traction is applied to the dome of the bladder; the lateral attachments of the bladder are divided to obtain better exposure. The midline incision is extended all the way down to the pubis. Between the bladder and posterior aspect of the pubis, one can see the space that was created from below with the total urogenital mobilization. The urogenital complex is then brought up through this space between bladder and pubis. At this point, we divide all the pelvic avascular attachments of the bladder and urethra. Through the laparotomy, these attachments are easily seen. Usually this maneuver allows us to gain extra length on the urogenital mobilization. If that is enough to complete our repair, we then pull back through the urogenital complex and repair the urethra and vagina as described previously.

### **Carving of the pubic cartilage**

If the extended transabdominal urogenital mobilization is not enough to achieve a tension-free anastomosis between

urethra and clitoris and vagina and neolabia, carving of the pubic cartilage is indicated. Under normal circumstances, the urogenital sinus is located behind the pubic cartilage. It runs below the cartilage and up, anterior to the cartilage to connect to the clitoris. Resecting approximately 50% of the posterior aspect of the pubic cartilage does not compromise pelvic stability but allows a more direct trajectory of the urogenital sinus. This maneuver may allow a tension-free anastomosis between urethra and vagina with the clitoris and neolabia. If that is not enough, then the next step must be the separation of the vagina from the urinary tract.

### **Separation of vagina(s) from the urinary tract**

This is the most technically demanding maneuver of the entire cloacal repair. This procedure used in the past for all cases before total urogenital mobilization was developed, was usually done through the perineal incision, which was very difficult. Now that we can deliver the total urogenital mobilization into the abdomen, the separation of these structures is much easier but still technically demanding. It is done through a laparotomy, with the bladder and vagina(s) fully mobilized. The bladder is opened in the midline and feeding tubes are introduced through each of the ureters because in cloaca patients both ureters pass through the common wall between the vagina and the bladder. The separation of these 2 structures may include the skeletonizing and dissection of both ureters. A plane is created in the middle of the wide common wall that exists between the vagina(s) and the urinary tract. This common wall extends from the urethra and includes bladder neck, trigone, and part of the bladder. To achieve a good repair, it is necessary to separate these structures with minimal or no damage.

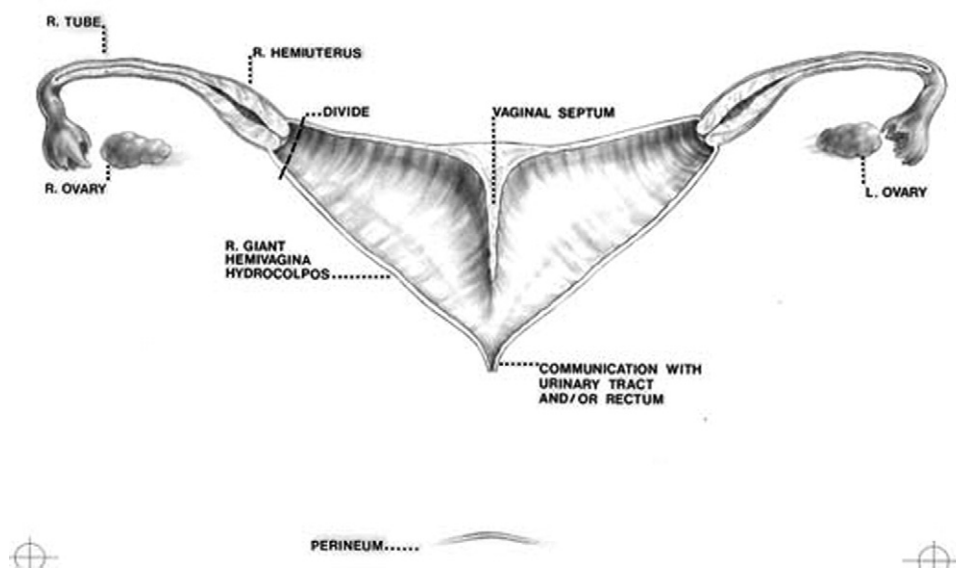
After the separation, the surgeon can plan the type of reconstruction that is best for the patient's specific anatomical variant. The first possibility is that after the separation, one finds that the vagina(s) reaches the perineum. This is the ideal time to remove the vaginal septum that separates the 2 hemivaginas and tubularize available vaginal tissue in preparation for the pull-through.

The total separation of vagina(s) and urinary tract carries the risk of devascularization of the distal urethra. It is necessary to be sure that the urethra that is sutured immediately behind the clitoris has a good blood supply.

Planning the reconstruction of vagina, urethra, and rectum after total separation of the structures, the surgeon faces one of several scenarios.

### **Vaginal switch (n = 48)**

The first possibility will be that the patient has anatomical characteristics that make her suitable for a surgical maneuver called the "vaginal switch." These patients have separated hemiuteri with a vaginal septum and 2 large hydrocolpi. If the distance between one hemiuterus and the other is longer than the vertical length of both hemivaginas, then the patient may be a candidate for the vaginal switch maneuver. As can be seen in [Figures 7 and 8](#), the maneuver



**Figure 7** Vaginal switch maneuver. The distance between 1 hemiuterus and the other is longer than the vertical length of both hemivaginas, which is ideal for a vaginal switch procedure. (Reprinted with permission.<sup>8</sup>)

sacrifices one of the hemiuteri and carefully preserves the ovary and its blood supply. The vaginal septum is removed. Both hydrocolpi are tubularized into a single vagina, and what used to be the dome of one side (the place where we resected the hemiuterus) becomes the lowest part of the new, switched down vagina. If, early in the operation, one realizes that the anatomy belongs to this category, one has to completely separate only 1 hemivagina from the urinary tract and try to preserve the blood supply on the opposite side. In this maneuver, the blood supply of the entire switched vagina will depend on the preservation of the blood supply of the opposite hemivagina.

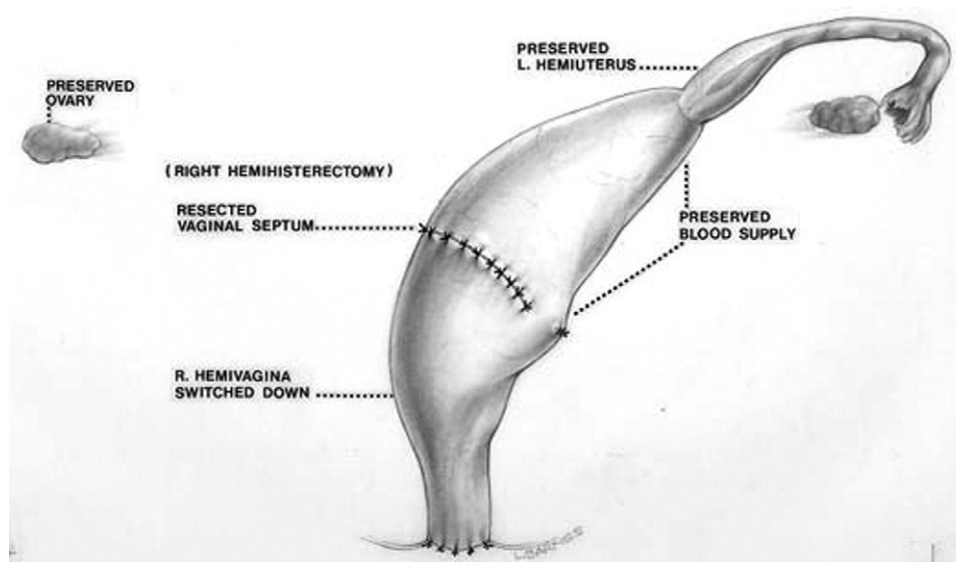
If the distance between both hemiuteri is not long enough, then both hemivaginas must be separated com-

pletely from the trigone and urinary tract as discussed previously, and a plan for an interposed segment of bowel between native vagina and perineum is required.

**Vaginal replacement (n = 90)**

For cloacas requiring a vaginal replacement, our order of preference in terms of choice of tissue for the replacement are rectum, descending colon, sigmoid colon, and finally small bowel.

*Vaginal replacement with rectum (n = 33).* There are several ways to replace the vagina with rectum. If the patient has a very dilated rectum, we can divide it longitudinally, preserving the blood supply of both portions, the segment that



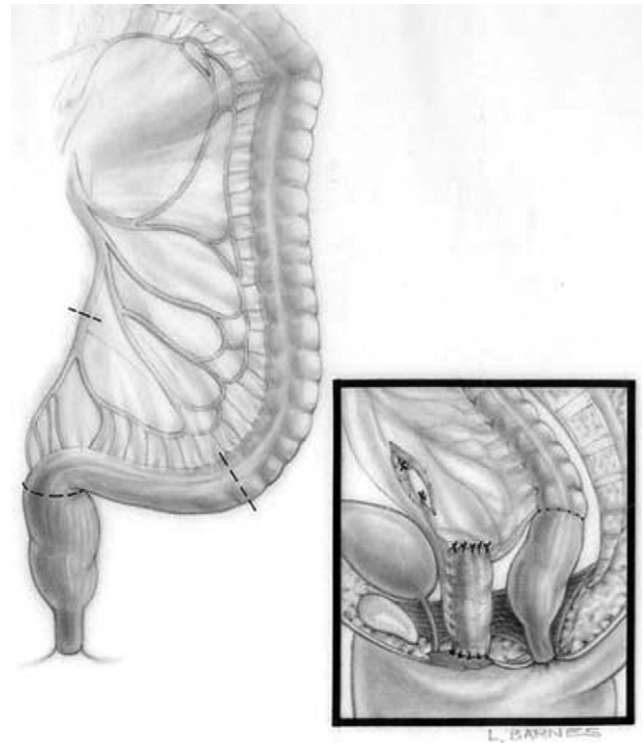
**Figure 8** Both hydrocolpi are tubularized into a single vagina, and what used to be the dome of 1 side (where we resected the hemi-uterus) becomes the lowest part of the new switched down vagina. (Reprinted with permission.<sup>8</sup>)

is going to be the neovagina and the one that will remain as rectum. The vagina and the rectum are both tubularized. Both structures are rotated 90° in opposite directions to avoid the overlap of suture lines. If the patient has no internal genitalia, then the vagina is created for sexual purposes only and is not anastomosed to any internal structures. If the patient has internal genitalia, then an anastomosis between the upper portion of the neovagina (original rectum) and the original native short vagina must be performed.

In patients with a nondilated rectum but with plenty of available rectal length, we can plan on using the most distal part of the rectum as a neovagina and mobilize the upper rectum as a neorectum. It is imperative to preserve the blood supply of the distal rectum. One must keep in mind that the mesentery of the rectum is completely different from the mesentery of the rest of the gastrointestinal tract. In the small bowel and colon, the mesentery reaches the bowel on the mesenteric side only. The rectum, by contrast, is completely surrounded by fatty tissue with vessels. To preserve the blood supply of the distal rectum, it is necessary to create a plane of separation between the bowel wall itself and the fatty tissue with vessels. The dissection between mesorectum and bowel wall is carried out all around the rectal wall at the place where we previously planned rectal division, leaving the distal part as neovagina and the proximal part as neorectum. Before making the decision to divide the rectum, we must be absolutely sure that we have enough proximal bowel length to reach the perineum without tension. If the patient has no internal genitalia, the neovagina (original rectum) is closed blind on its upper end and will be used only for sexual purposes.

*Vaginal replacement with colon (n = 15).* If the rectum is not adequate for vaginal replacement, then our next choice is colon. We have typically used the sigmoid colon when available (Figure 9) or the descending colon, which has a nice vascular arcade of vessels. A good option is to take the colostomy down and use the part that used to be the colostomy to replace the vagina. The pedicle of the left colon graft often reaches the perineum more easily than the sigmoid.

*Vaginal replacement using small bowel (n = 42).* The blood supply of the small bowel is more delicate and more prone to suffer occlusion with a mild twist of the pulled down bowel pedicle. When we decide to use small bowel, we prefer to use terminal ileum. An interesting observation is that the length of the mesentery at the cecum represents the length of the superior mesenteric axis (Figure 10). If one takes the terminal ileum about 10 cm proximal to the ileocecal valve, it is easy to see that the mesentery is longer than at the cecum, and if we go even more proximal, the mesentery is even longer. The longest mesentery of the small bowel seems to be located about 15 cm proximal to the ileocecal valve, and because of that, this part of the bowel is



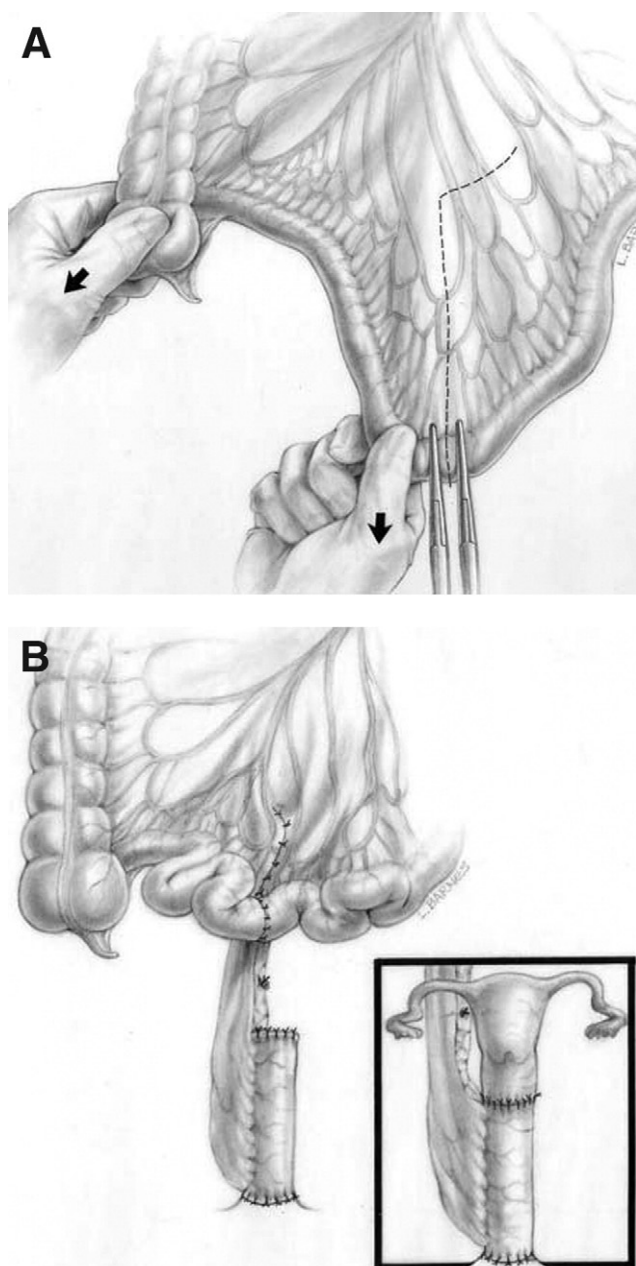
**Figure 9** Vaginal replacement with sigmoid colon. (Reprinted with permission.<sup>8</sup>)

ideal for vaginal replacement. Accordingly, we manipulate the blood supply to be sure that the bowel reaches the perineum. Again, one must be extremely meticulous pulling down the bowel, because a little twist will produce ischemia. If the patient has internal genitalia, then, as previously mentioned, the small bowel (neovagina) is anastomosed to the internal genitalia and to the new labia. By contrast, if the patient has no internal genitalia, the neovagina's upper part is closed, and only an anastomosis to the neolabia is performed.

### **Cloacas with greater than 5 cm common channel (n = 47)**

When endoscopy demonstrates that the patient has an extremely long common channel (>5 cm), separation of the structures (rectum, vagina, and urinary tract) can be done more easily at laparotomy than through the posterior sagittal approach. The anatomy is illustrated in Figure 11. The rectum opens either into the bladder neck or the trigone, 2 little hemivaginas also open in the trigone or the bladder neck in a perpendicular manner (with no common wall), and the ureters open in that area as well. The separation of these structures may leave the patient without a bladder neck, or with a damaged structure. Good clinical judgment and experience are required to make a decision about reconstructing the bladder neck.

By approaching these patients through a laparotomy, one can leave the common channel intact for use as a conduit for



**Figure 10** (A, B) Vaginal Replacement with Small Bowel. (Reprinted with permission.<sup>8</sup>)

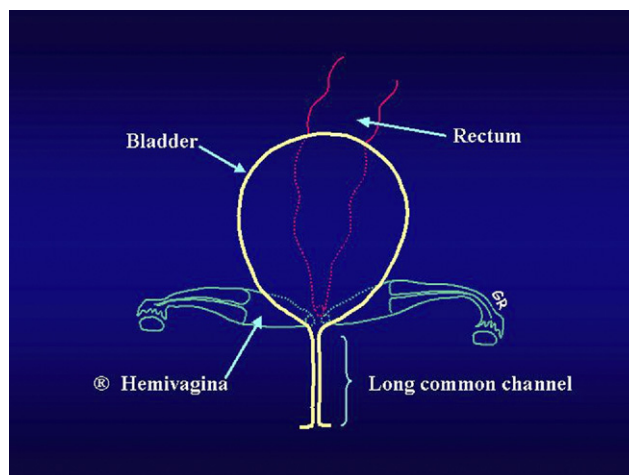
intermittent catheterization; and that will work well as the urethra, provided the bladder neck is adequately reconstructed.

Patients with cloacas almost always have a good bladder neck and can hold urine in the bladder. Their main type of bladder malfunction is an inability to empty.<sup>10</sup> They have a smooth, large, floppy bladder with a good bladder neck, but cannot empty the bladder; therefore, during the period of filling of the bladder, the patient may remain completely dry. After the bladder is completely full, they start dribbling urine as an overflow phenomenon. Therefore, they are ideal candidates for intermittent catheterization.

Occasionally, laparotomy is indicated because of a very high rectum, and not because of the urogenital tract. Sometimes, the rectum opens very high in between both hemivaginas and cannot be reached by the posterior sagittal approach, even after total urogenital mobilization has been performed. Therefore, one has to enter the abdomen just to identify the rectum and pull it down. This unique type of case might be ideal for laparoscopy.

### Postoperative management

In some instances, we repair these malformations and pull the colostomy down for vaginal replacement at the same time. In those cases, because the patient no longer has fecal diversion, they are maintained with nothing by mouth, and receive parenteral nutrition for 7-10 days. Most of the time, however, the colostomy remains intact, and the patient can eat when their postoperative ileus has resolved. They usually stay in the hospital 2-5 days. A Foley catheter remains in place for 2 to 3 weeks. Approximately 20% of these patients may eventually require intermittent catheterization and, therefore, we leave the Foley catheter until the postoperative swelling has receded and we can see where the urethral meatus is located. Two weeks after the procedure, we teach the parents how to dilate the anal orifice. Before colostomy closure and under the same anesthesia, vaginoscopy and cystoscopy are performed to confirm that the urethra and vagina are patent and healthy in appearance and there is no fistula between them, and that there is no rectal or vaginal prolapse. If any of these problems are noted, they have to be taken care of before colostomy closure. Sometimes the urethra is difficult to catheterize. In such cases it might be appropriate to perform a vesicostomy, and delay intermittent catheterization until the baby is older.



**Figure 11** Typical appearance of a 5.0 cm or longer common channel cloaca. (Reprinted with permission.<sup>8</sup>)

## Conclusions

The newborn management and definitive reconstruction of cloacal malformations requires knowledge of the broad spectrum of defects. With proper treatment, these patients can undergo an excellent anatomical repair and can be clean and dry.

## References

1. Peña A, Levitt MA. Surgical management of cloacal malformations. *Semin Neonatol* 2003;8:249-57.
2. Levitt MA, Peña A. Pitfalls in the management of newborn cloacas. *Pediatr Surg Int* 2005;21:264-69.
3. Breech L. Gynecologic concerns in patients with anorectal malformations. *Semin Pediatr Surg* 2010;19:139-45.
4. Hendren WH. Cloacal malformations: experience with 105 cases. *J Pediatr Surg* 1992;27:890-901.
5. Peña A, Levitt MA. Imperforate anus and cloacal malformations. In: Ashcraft KW, Holcomb GW, Murphy JP, eds. *Pediatric Surgery*. 4th ed. Philadelphia, PA: Elsevier Saunders, 2005:496-517.
6. Peña A. The surgical management of persistent cloaca: results in 54 patients treated with a posterior approach. *J Pediatr Surg* 1989;24:590-598.
7. Peña A. Total urogenital mobilization: an easier way to repair cloacas. *J Pediatr Surg* 1997;32:263-7; discussion 267-268.
8. Peña A, Levitt MA, Hong AR, et al. Surgical management of cloacal malformations: a review of 339 patients. *J Pediatr Surg* 2004;39:470-479.
9. Patel M, Racadio J, Peña A, et al. Complex cloacal malformations: use of rotational fluoroscopy and 3-D reconstruction in diagnosis and surgical planning. Presented at: Annual meeting of the Radiological Society of North America; November 29, 2006; Chicago, IL; Abstract.
10. Peña A, Levitt MA. Neurogenic bladder and anorectal malformations. In: Esposito C, Guys JM, Gough D, Savanelli A, eds. *Pediatric Neurogenic Bladder Dysfunction*. Berlin: Springer, 2006: 85-8.